

ORIGINAL ARTICLE

Right ventral stream damage underlies both poststroke aprosodia and amusia

Aleksi J. Sihvonen^{1,2}  | Daniela Sammler³ | Pablo Ripollés⁴ | Vera Leo¹ | Antoni Rodríguez-Fornells^{5,6,7} | Seppo Soinila⁸ | Teppo Särkämö¹

¹Cognitive Brain Research Unit, Department of Psychology and Logopedics, Faculty of Medicine, University of Helsinki, Helsinki, Finland

²Centre for Clinical Research, University of Queensland, Brisbane, Queensland, Australia

³Research Group "Neurocognition of Music and Language, Max Planck Institute for Empirical Aesthetics, Frankfurt am Main, Germany

⁴Department of Psychology, New York University, New York, New York, USA

⁵Cognition and Brain Plasticity Group, Bellvitge Biomedical Research Institute, L'Hospitalet de Llobregat, Spain

⁶Department of Cognition, Development, and Education Psychology, University of Barcelona, Barcelona, Spain

⁷Catalan Institution for Research and Advanced Studies, Barcelona, Spain

⁸Neurocenter, Turku University Hospital and Division of Clinical Neurosciences, University of Turku, Turku, Finland

Correspondence

Aleksi J. Sihvonen, Cognitive Brain Research Unit, Department of Psychology and Logopedics, FI-00014 University of Helsinki, Haartmaninkatu 3, P.O. Box 21, Helsinki, Finland.

Email: aleksi.sihvonen@helsinki.fi

Funding information

Suomen Akatemia, Grant/Award Number: 257077, 277693 and 299044; Signe ja Ane Gyllenbergin Säätiö; Suomen Kulttuurirahasto, Grant/Award Number: 191230; Orionin Tutkimussäätiö

Abstract

Background and purpose: This study was undertaken to determine and compare lesion patterns and structural dysconnectivity underlying poststroke aprosodia and amusia, using a data-driven multimodal neuroimaging approach.

Methods: Thirty-nine patients with right or left hemisphere stroke were enrolled in a cohort study and tested for linguistic and affective prosody perception and musical pitch and rhythm perception at subacute and 3-month poststroke stages. Participants listened to words spoken with different prosodic stress that changed their meaning, and to words spoken with six different emotions, and chose which meaning or emotion was expressed. In the music tasks, participants judged pairs of short melodies as the same or different in terms of pitch or rhythm. Structural magnetic resonance imaging data were acquired at both stages, and machine learning-based lesion-symptom mapping and deterministic tractography were used to identify lesion patterns and damaged white matter pathways giving rise to aprosodia and amusia.

Results: Both aprosodia and amusia were behaviorally strongly correlated and associated with similar lesion patterns in right fronto-insular and striatal areas. In multiple regression models, reduced fractional anisotropy and lower tract volume of the right inferior fronto-occipital fasciculus were the strongest predictors for both disorders, over time.

Conclusions: These results highlight a common origin of aprosodia and amusia, both arising from damage and disconnection of the right ventral auditory stream integrating rhythmic-melodic acoustic information in prosody and music. Comorbidity of these disabilities may worsen the prognosis and affect rehabilitation success.

KEYWORDS

amusia, aprosodia, lesion-symptom mapping, stroke, tractography

INTRODUCTION

Poststroke aphasia is a common language disorder that occurs after cortical damage and white matter (WM) disconnections in dorsal

(sound-to-articulation) and ventral (sound-to-meaning) streams in the left hemisphere [1]. Communication hinges, however, on more than words. It requires the ability to extract meaning from prosody, that is, the melody and rhythm in speech. Prosody lends structure

See commentary by E. Altenmüller on page 689

to the speech stream by marking boundaries, signaling emphasis, or determining lexical meanings (e.g., the difference between “greenhouse” and “green house”). Moreover, prosody conveys emotional states of the speaker. These functions, respectively, are classically subsumed under the terms *linguistic* and *affective* prosody [2]. Perturbations of prosody perception (aprosoia) [3,4] affect approximately 30% of right hemisphere stroke patients [5] and have a strong negative impact on patients' social relationships [6] and well-being [7].

Linguistic and affective prosody perception has been proposed to rely on dorsal and ventral streams in the right hemisphere [8,9], that is, frontotemporal regions interconnected dorsally via the arcuate fasciculus (AF) and ventrally via the inferior fronto-occipital fasciculus (IFOF). These streams stand in dynamic exchange with the left hemisphere language networks via the corpus callosum (CC) [10–12]. Although prosody perception deficits have been associated with right-hemispheric damage [4,13,14], especially with frontotemporal cortical structures belonging to the ventral stream [15,16], only little is known about the role of WM damage in aprosoia [17]. Modern lesion studies endorsing a hodological approach to prosodic deficits are lacking [18].

Defective processing of rhythmic-melodic acoustic patterns also occurs in the musical domain—in poststroke amusia, a common deficit affecting up to 60% of acute stroke patients [19,20]. Like aprosoia, amusia has been associated with right ventral stream damage [21–23], including perturbations of the IFOF. This suggests coincident impairments in prosody and music perception. However, comparative studies evaluating a potentially shared neuroanatomical basis of aprosoia and amusia are lacking.

Here, we evaluate and compare damaged neural structures underlying deficits in prosody and music perception using lesion-symptom mapping [24] and diffusion tensor imaging (DTI), at subacute and 3-month stages in a sample of 39 stroke patients. Based on small-scale lesion studies on prosodic deficits [4,13–15,25], lateralization of affective speech processing in the healthy brain [26,27] and previous evidence on amusia [21–23], we hypothesize that both disabilities arise from overlapping lesions in the right hemisphere, particularly from damage and disconnection of the right ventral stream.

MATERIALS AND METHODS

Subjects and study design

We present data of 39 patients (17 female and 22 male, mean age = 56.5 years, SD = 14.7) hospitalized between 2013 and 2015 at the Neurocenter, Turku University Hospital for an acute ischemic stroke ($n = 28$) or intracerebral hemorrhage ($n = 11$) in the left ($n = 21$) or right hemisphere ($n = 18$) with subsequent cognitive and motor deficits. Inclusion criteria were acute unilateral stroke, right-handedness, <80 years of age, capability to communicate in Finnish, residence in southwest Finland, ability to cooperate, and normal hearing.

Patients with prior neurological or psychiatric disease or substance abuse were not included. Most patients (82%) had a stroke within the middle cerebral artery territory, and 18% had a stroke within the posterior cerebral artery territory, with a mean lesion size of 50.1 ml (SD = 50.3). Written informed consent in accordance with the Declaration of Helsinki was acquired from all patients, and the protocol was approved by the Ethics Committee of the Hospital District of Southwest Finland. No ethnic data were collected. All patients underwent magnetic resonance imaging (MRI) and neuropsychological assessments within 3 weeks after stroke onset (mean = 12.1 days, SD = 5.5) and 3 months poststroke (mean = 100 days, SD = 8.8). Two time points were used to ascertain the stability of the findings. All patients received standard care and rehabilitation for stroke. There were no missing data.

Assessment of prosody and music perception

Prosody perception was evaluated with two well-validated tasks. In the linguistic prosody task [28], 30 utterances with different prosodic word stress patterns were played to the patients via headphones. Word stress denoted either a compound word or a phrase composed of two words, for example, “KISSankello” and “KISSan KELLO” (comparable to English “BLUEbell” referring to the name of a flower and “BLUE BELL” referring to a colored ringing object). After each utterance, patients were asked to select via button press one of two pictures on a screen matching what they had heard.

In the affective prosody task [29], patients were presented with 96 one-word utterances (“Saara”, a female first name) spoken with happy, sad, angry, afraid, surprised, or neutral prosody. Patients were asked to select which of the six emotions displayed on screen was expressed by pressing one of six buttons.

Music perception was assessed with a shortened version [30] of the Montreal Battery of Evaluation of Amusia (MBEA) [31]. Both subtests comprise 14 pairs of short piano melodies, half of which are identical and half of which contain a musically altered tone in the second melody. Patients were asked to judge on each trial whether the two melodies sounded identical. In the Scale subtest, the altered tones have an out-of-scale pitch change. In the Rhythm subtest, the alteration is a change in the duration values of two adjacent tones in the melody. MBEA Scale and Rhythm subtests were used separately as indices of musical pitch and rhythm perception, respectively.

Scores on both prosody and music tests at both time points were converted to percentage-correct scores and used in the analyses.

According to the established cutoff values of the MBEA, 21 patients were amusical at the subacute stage, and 16 at the 3-month stage. For the two tests used to assess prosody perception, no clear cutoff values have been established. However, comparable neurologically healthy listeners have a mean score of 83%, with SD = 9% [28]. Following the cutoff values for MBEA, patients scoring 2 SD below the healthy listeners were classified as aprosodic (i.e., <65%; mean score of the two prosody tests). At the subacute and 3-month stages, 24 and 16 patients were classified as aprosodic, respectively.

MRI data acquisition and preprocessing

Patients were scanned on a 3-T Siemens Magnetom Verio scanner at the Department of Radiology of Turku University Hospital. T1-weighted anatomical scans (flip angle = 9°, repetition time [TR] = 2300 ms, echo time [TE] = 2.98 ms, voxel size = 1.0 × 1.0 × 1.0 mm³) were acquired as well as diffusion MRI scans (TR = 11,700 ms, TE = 88 ms, acquisition matrix = 112 × 112, 66 axial slices, voxel size = 2.0 × 2.0 × 2.0 mm³) with one non-diffusion-weighted volume and 64 diffusion-weighted volumes (b-value = 1000 s/mm²).

T1 images were preprocessed using a previously reported pipeline [21,23] using Statistical Parametric Mapping (SPM8) under MATLAB v8.4.0. Unified Segmentation with medium regularization and cost function masking was applied to achieve accurate segmentation and optimal normalization in stroke patients with lesioned brain tissue. Lesion tracing was performed manually and separately for each time point by the first author (A.J.S.) using MRICron (<https://www.nitrc.org/projects/mricron>). The segmented T1 images were modulated, normalized to Montreal Neurological Institute (MNI) space. Lastly, the binary lesion masks were registered to MNI space.

Diffusion MRI data were processed using the FMRIB Software Library (FSL v5.0.8, www.fmrib.ox.ac.uk/fsl). First, eddy current distortions and head motions were corrected followed by gradient matrix rotation using FSL's `fdt rotate bvecs`. Then, brain extraction was performed using the Brain Extraction Tool. The diffusion tensors were reconstructed using the linear least-squares algorithm included in Diffusion Toolkit v0.6.2.2 (www.trackvis.org/dtk).

Voxel-based lesion-symptom mapping

Lesion-symptom relations were evaluated with multivariate lesion-symptom mapping using support vector regression (SVR-LSM) with SVR-LSM GUI [24,32]. Eight separate SVR-LSM analyses were carried out using linguistic prosody, affective prosody, MBEA Scale, and MBEA Rhythm scores at subacute and 3-month stages. All voxels damaged in at least 10% of the patients were included in the statistical analysis. SVR-β-value maps were generated using 1000 permutations, catalogued on a voxelwise basis, and thresholded at $p < 0.005$. Multiple comparisons were accounted for at a familywise error rate of $p < 0.00625$ at the cluster level (Bonferroni-corrected). Lesion volume was controlled regressing it from both lesion and behavioral data [24,32]. Brain areas were labeled based on the Automated Anatomical Labelling Atlas (<http://www.alivelearn.net/xjview>).

Diffusion MRI: Deterministic tractography

The DTI analyses focused on the AF, IFOF, CC, and tapetum, as these tracts have been implicated in both prosody perception and amusia [8,10,11,15,19,23]. Furthermore, based on our study hypotheses and the expected right-lateralization of results, right inferior longitudinal

fasciculus and uncinate fasciculus were also dissected. All tracts were dissected manually using deterministic tractography in TrackVis (v0.6.0.1). AF and IFOF were dissected in both hemispheres. AF was dissected in its three segments: the long segment connecting frontal and temporal lobe, the anterior segment connecting frontal and parietal lobe, and the posterior segment connecting temporal and parietal lobe. For further details, please see Sihvonen et al. [23].

Volume and mean fractional anisotropy (FA) of each dissected tract were extracted using a MATLAB toolbox [33] and imported into IBM SPSS Statistics 24. We tested which parameters of which tracts explained performance in the prosody and music tasks using eight stepwise regression analyses, one for each of the four behavioral scores at the subacute and 3-month stages as dependent variable. The two WM tract parameters of each of the 12 dissected tracts served as 24 independent variables in all models. Alpha level on each model was set to 0.00625 (Bonferroni-corrected).

RESULTS

Behavioral deficits in prosody and music perception

First, the behavioral relationship of prosody and music perception was evaluated using two-tailed Pearson correlations (Bonferroni-corrected). These showed significant positive correlations between (i) linguistic prosody and affective prosody (subacute: $r = 0.71$, $p < 0.001$; 3-month: $r = 0.53$, $p < 0.001$), (ii) linguistic prosody and music perception (MBEA Scale subacute: $r = 0.62$, $p < 0.001$; 3-month: $r = 0.54$, $p < 0.001$; MBEA Rhythm subacute: $r = 0.63$, $p < 0.001$, 3-month: $r = 0.58$, $p < 0.001$), and (iii) affective prosody and music perception (MBEA Scale subacute: $r = 0.66$, $p < 0.001$; 3-month: $r = 0.62$, $p < 0.001$; MBEA Rhythm subacute: $r = 0.59$, $p < 0.001$; 3-month: $r = 0.59$, $p < 0.001$).

Lesion patterns associated with poor prosody and music perception

Lesion-symptom mapping revealed exclusively right-hemispheric lesion patterns including fronto-insular and striatal areas for both prosodic deficits and amusia. First, lesion patterns comprising right insula or basal ganglia were associated with poor linguistic (subacute and 3-month stages) and affective prosody perception (3-month stage; Table 1, Figure 1a,b). At the subacute stage, the lesion pattern associated with linguistic prosodic deficit was centered on frontal WM and extended further into right Rolandic operculum and limbic structures (Table 1, Figure 1a).

Second, pitch and rhythm amusia were also associated with lesion patterns comprising right frontal, insular, and basal ganglia areas (Table 1, Figure 1c,d), closely resembling the regions associated with prosodic deficits. Beyond the lesion pattern shared by pitch and rhythm amusia, subacute stage pitch amusia spread more ventrally, reaching the temporal lobe and limbic regions (Table 1, Figure 1c).

| Condition | Hemisphere & region | Subacute stage | 3-month stage |
|----------------------|---------------------|------------------|--------------------|
| Linguistic aprosodia | R frontal | IFG, ROP, insula | Insula |
| | R basal ganglia | Put, Pall, Caud | Put, Pall |
| | R limbic | Amy, Thal | — |
| Affective aprosodia | R basal ganglia | — | Put, Pall |
| Pitch amusia | R frontal | IFG, ROP, insula | IFG, PreCG, insula |
| | R temporal | STG, TTG | — |
| | R basal ganglia | Put, Caud, Pall | Put, Pall, Caud |
| | R limbic | Amy, Thal | — |
| Rhythm amusia | R frontal | ROP, insula | Insula |
| | R basal ganglia | Put | Put, Pall |

Note: All results are thresholded at voxelwise $p < 0.005$ and clusterwise familywise error rate $p < 0.00625$.

Abbreviations: Amy, amygdala; Caud, caudate; IFG, inferior frontal gyrus; Pall, globus pallidum; PreCG, precentral gyrus; Put, putamen; R, right; ROP, Rolandic operculum; STG, superior temporal gyrus; Thal, thalamus; TTG, transverse temporal gyrus.

The right-lateralization of poor prosody and music perception was also mirrored in the direct comparison of performance after left- and right-hemisphere stroke. At both stages, right-hemispheric patients had significantly lower linguistic prosody (subacute: $t[37] = 2.579$, $p = 0.014$; 3-month: $t[37] = 2.344$, $p = 0.025$), MBEA Scale (subacute: $t[37] = 3.971$, $p < 0.001$; 3-month: $t[37] = 3.840$, $p < 0.001$), and MBEA Rhythm scores (subacute: $t[37] = 3.101$, $p = 0.004$; 3-month: $t[37] = 2.482$, $p = 0.018$) than left-hemispheric patients. Affective prosody only reached significance 3 months poststroke (subacute: $p = 0.072$; 3-month: $t[37] = 2.540$, $p = 0.015$).

WM pathways associated with poor prosody and music perception

Following hodological views of brain function [18], we then examined parameters of relevant frontotemporal WM tracts as predictors of patients' performance in prosody and music tasks. In all but one task (subacute rhythm perception) and consistently across both stages, weaker performance was explained by damage of the right IFOF, denoted by smaller volume or lower FA (mean R^2 change = 27% across seven models). This consistent involvement of the right IFOF further supports the crucial necessity of intact right ventral connectivity for normal prosody and music perception (Table 2, Figure 2). In addition to the right IFOF, FA of the CC and volume of the right uncinate fasciculus explained variance in affective prosody perception at the subacute stage and 3-month stage, respectively. Furthermore, tract parameters of the right AF were related to pitch perception at both stages. Volume of the right AF (long segment) was the main predictor of rhythm perception at the subacute stage, whereas disconnection of right IFOF and left AF (and preserved connectivity of left IFOF) explained rhythm perception at the 3-month stage.

TABLE 1 Lesion–symptom mapping results

DISCUSSION

The present multimodal neuroimaging study identified and compared lesion patterns and WM disconnections underlying deficits in prosody and music perception in a sample of 39 subacute stroke patients followed up at 3 months poststroke. Our main findings were (i) that both linguistic and affective prosodic deficits are explained by disconnections of the right IFOF together with lesions along the right ventral stream, and (ii) that similar lesion configurations also give rise to both pitch and rhythm amusia. Our findings argue for a frequent behavioral and anatomical coupling of poststroke aprosodia and amusia. This comorbidity has important implications for patients' well-being and rehabilitation success.

Right ventral stream damage underlies prosodic deficits

Poor linguistic and affective prosody perception was associated with right frontoinsula and basal ganglia lesions. Moreover, damage to the right IFOF was the strongest predictor of both prosodic deficits at both time points studied. Poor affective prosodic perception at the 3-month stage was additionally associated with damage to the right uncinate fasciculus. No consistent involvement of left hemisphere structures or of the right AF was found. These combined data highlight the damage and disconnection of right IFOF, and associated areas, as the most likely causes of poststroke deficits in prosody perception. The right ventral stream has been suggested to play a critical role in prosody perception [8,15,16], but larger DTI studies evaluating the necessity of WM tracts have been lacking [17]. The right IFOF interconnects right frontal, temporal, and inferior parietal/occipital areas and is a major anatomical ventral stream pathway [34,35]. Its cortical termination points are known to be active during both linguistic and affective prosody perception [36]. Affective

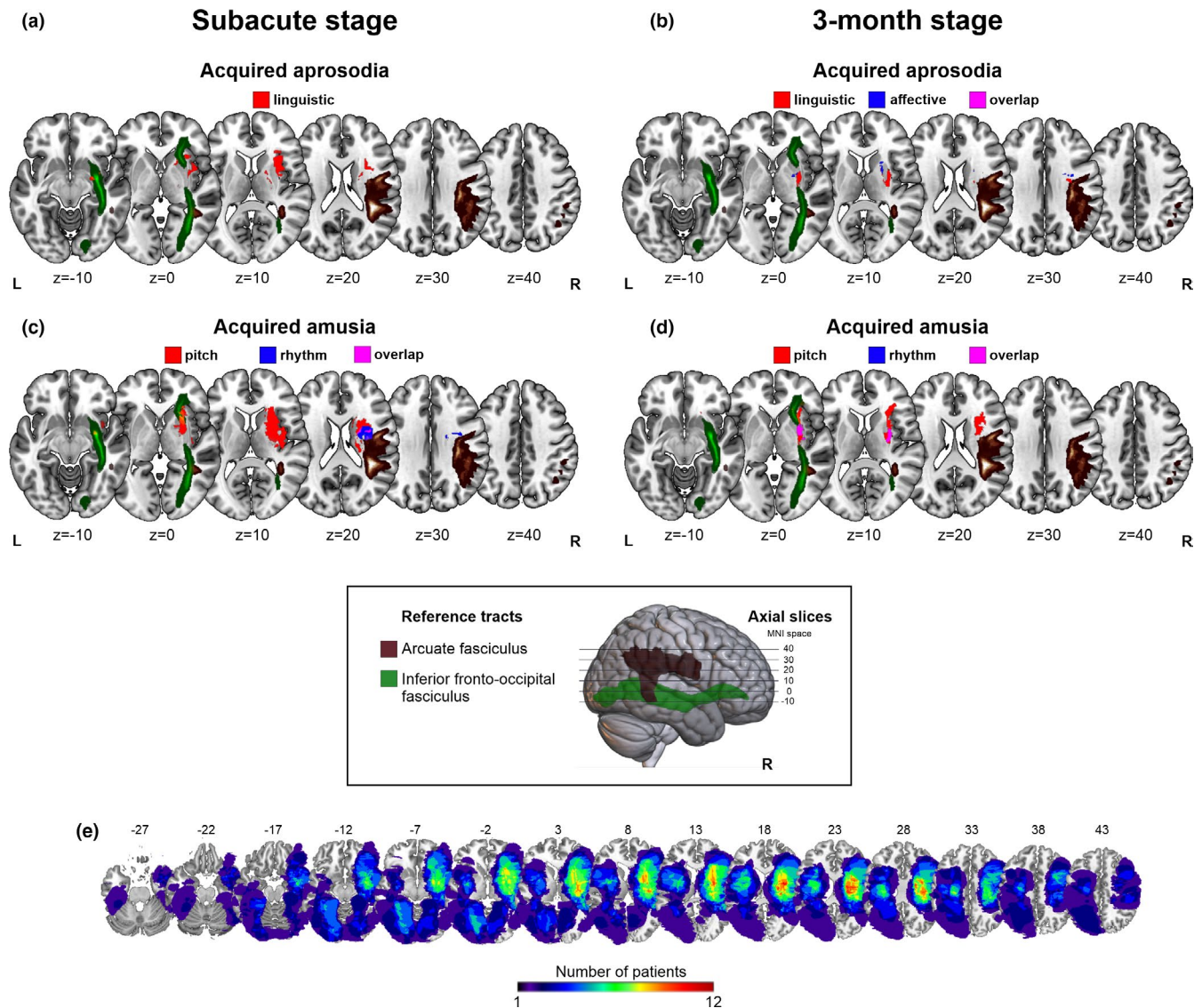


FIGURE 1 Lesion patterns associated with poor prosody and music perception. (a–d) Lesion patterns linked to deficits in linguistic (red) and affective prosody perception (blue), musical pitch (red) and rhythm perception (blue), and their within-domain overlap (pink) at the subacute stage (left [L]) and 3-month stage (right [R]). Neurological convention is used with axial Montreal Neurological Institute (MNI) coordinates at the bottom of each slice. All statistical maps are thresholded at voxelwise $p < 0.005$ and clusterwise familywise error rate $p < 0.00625$. A reference map of appropriate white matter tracts is presented (<http://www.natbrainlab.co.uk/atlas-maps>). (e) Lesion distribution in the whole sample ($N = 39$). The warmer the colors, the more patients had a lesion in this area, ranging from 1 to 12 patients

prosody perception additionally engages the right temporal pole, at which the right uncinate terminates.

The lesion patterns reported here map onto stream models of prosody perception [8,16] according to which the brain encodes prosodic information in (right) superior temporal regions [15] and integrates this information over time along the posterior-to-anterior axis of the temporal lobe [37], before cognitively evaluating its emotional or linguistic significance in inferior frontal regions [9,16]. Our data suggest that the disconnection of frontotemporal regions due to right IFOF lesions (and to a lesser degree right uncinate fasciculus lesions) hinders this prosodic information flow and, hence, gives rise to prosodic deficits. Moreover, severe enough damage to either of

the frontotemporal termination territories of the right IFOF can also disrupt this processing chain, resulting in comparable deficits [34].

A recent study on affective aprosodia with a focus on right ventral stream regions of interest [15] reported right posterior superior temporal and amygdala lesions, but not frontal damage, as the best predictors of affective aprosodia, in line with earlier small-scale lesion studies [3]. Notably, these findings and our results are not mutually exclusive under the present hodological view; lesions in temporal termination regions of IFOF [35] can lead to similar disconnections and deficits as observed in the present study. Likewise, it cannot be excluded that these previous results emerge from damage to the right IFOF. Moreover, the lack of

TABLE 2 Results of the DTL multiple regression models

| 3-month stage | | | | | | | | | | | | | | | | |
|-------------------------------|----------------|----------|-------|--------|-------------------|-------|----------------|-----------------------|-------|-----------------|--------|-------|--------|-------------------|----------------|-----------------------|
| Subacute stage | Model | Variable | Beta | T | p | F(df) | R ² | R ² change | Model | Variable | Beta | T | p | F(df) | R ² | R ² change |
| Linguistic prosody perception | | | | | | | | | | | | | | | | |
| 1 | R IFOF vol. | 0.471 | 3.245 | 0.002 | F(1, 37) = 10.528 | 0.222 | 0.222 | 0.222 | 1 | R IFOF FA | 0.537 | 3.875 | <0.001 | F(1, 37) = 15.019 | 0.289 | 0.289 |
| Affective prosody perception | | | | | | | | | | | | | | | | |
| 1 | CC FA | 0.462 | 3.167 | 0.003 | F(1, 37) = 10.031 | 0.213 | 0.213 | 0.213 | 1 | R IFOF vol. | 0.617 | 4.769 | <0.001 | F(1, 37) = 22.746 | 0.381 | 0.381 |
| 2 | CC FA | 0.418 | 3.050 | <0.001 | F(2, 36) = 9.043 | 0.334 | 0.121 | 0.121 | 2 | R IFOF vol. | 0.624 | 5.026 | <0.001 | F(2, 36) = 14.453 | 0.445 | 0.065 |
| | R IFOF vol. | 0.351 | 2.559 | | | | | | | R Uncinate vol. | 0.356 | 2.380 | | | | |
| Pitch perception | | | | | | | | | | | | | | | | |
| 1 | R IFOF FA | 0.453 | 3.167 | 0.004 | F(1, 37) = 9.571 | 0.206 | 0.206 | 0.206 | 1 | R IFOF vol. | 0.544 | 3.946 | <0.001 | F(1, 37) = 15.571 | 0.296 | 0.296 |
| 2 | R IFOF FA | 0.371 | 3.050 | <0.001 | F(2, 36) = 8.524 | 0.321 | 0.116 | 0.116 | 2 | R IFOF vol. | 0.381 | 2.666 | <0.001 | F(2, 36) = 12.393 | 0.408 | 0.408 |
| | R AF Ant FA | 0.350 | 2.559 | | | | | | | R AF post FA | 0.372 | 2.604 | | | | |
| Rhythm perception | | | | | | | | | | | | | | | | |
| 1 | R AF Long vol. | 0.463 | 3.178 | 0.003 | F(1, 37) = 10.100 | 0.214 | 0.214 | 0.214 | 1 | R IFOF vol. | 0.601 | 4.569 | <0.001 | F(1, 37) = 20.877 | 0.361 | 0.361 |
| | | | | | | | | | 2 | R IFOF vol. | 0.667 | 2.666 | <0.001 | F(2, 36) = 16.894 | 0.483 | 0.123 |
| | | | | | | | | | | L IFOF vol. | -0.356 | 2.604 | | | | |
| | | | | | | | | | 3 | R IFOF vol. | 0.622 | 2.666 | <0.001 | F(3, 35) = 13.898 | 0.544 | 0.060 |
| | | | | | | | | | | L IFOF vol. | -0.345 | 2.604 | | | | |
| | | | | | | | | | | L AF Long vol. | 0.250 | | | | | |

Note: All models are significant at $p < 0.00625$.

Abbreviations: AF, arcuate fasciculus; Ant, anterior; Beta, standardized regression coefficient; CC, corpus callosum; F(df), F-value (degrees of freedom); FA, fractional anisotropy; IFOF, inferior fronto-occipital fasciculus; L, left; R, right; R², R-squared (unadjusted); T, t-value; vol., volume.

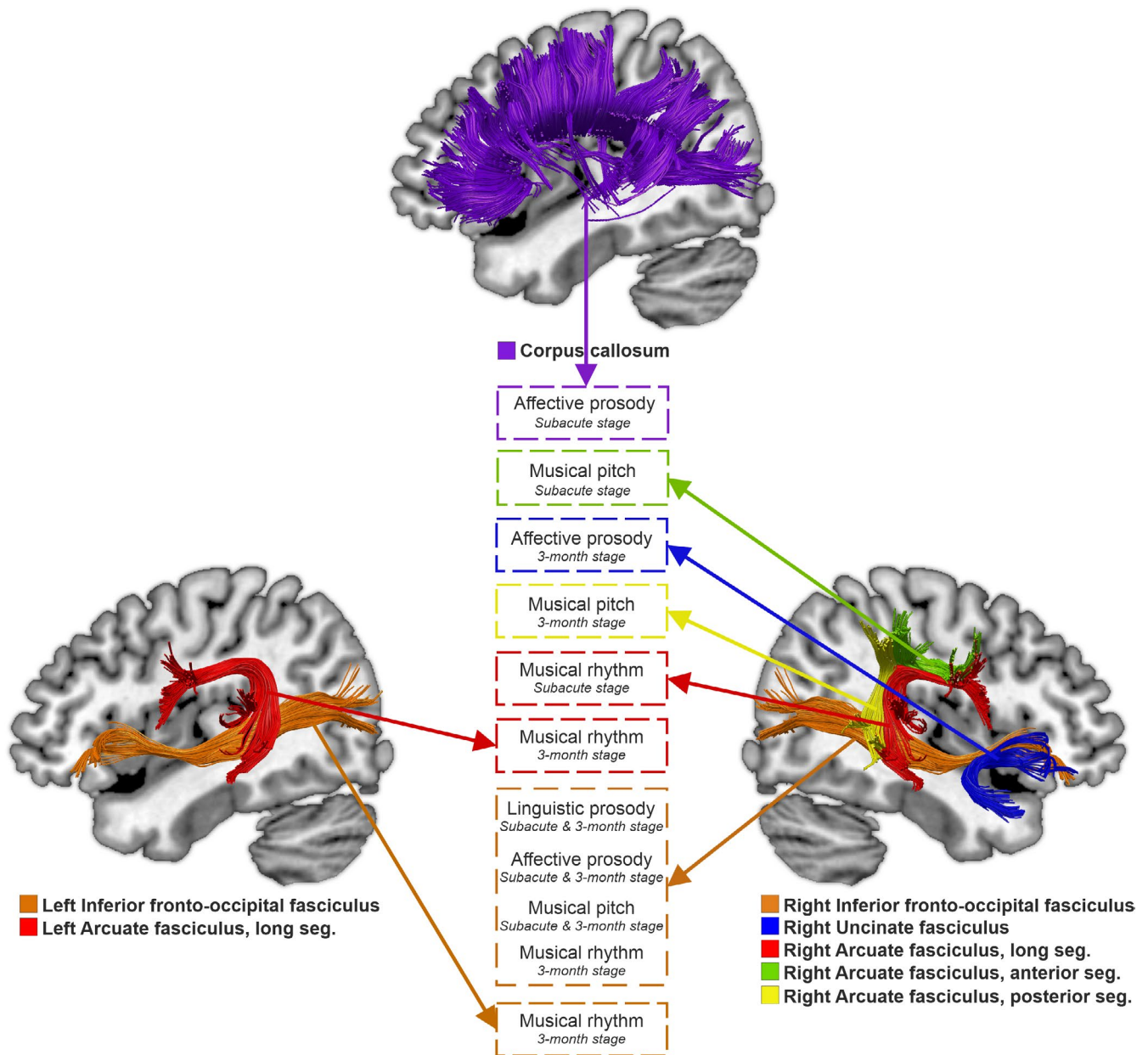


FIGURE 2 White matter tracts associated with prosody and music perception. White matter tracts whose parameters significantly predicted prosody (linguistic, affective) or music perception (pitch, rhythm) at the subacute and 3-month stages are displayed. Boxes specify the results for tasks and stages (Table 2). seg., segment

frontal involvement in the previous study [15] may be explained by the limited number of patients with frontal lesions, and the lack of posterior temporal or amygdala involvement in the present study could be partly due to our strict statistical thresholding to control for multiple comparisons, highlighting only the most robustly involved areas.

Additionally, right basal ganglia were associated with both types of prosodic deficits, highlighting the role of subcortical brain regions in prosody perception, in line with previous studies arguing for a role of the basal ganglia in sequencing and sensory-cognitive integration of auditory prosodic information [38,39]. Studying patients with lesions restricted to the basal ganglia, yet sparing the IFOF, could

shed further light on the specific roles of these regions in prosody perception.

There has been a longstanding debate on the lateralization of linguistic and/or affective prosody perception, depending on different (linguistic/affective) function or shared acoustic cues [13,14,36]. Notably, in the present study, all lesions related to poor prosody (and music) perception were right-lateralized. Overall, the present data support the proposal that fundamental acoustic dimensions of prosody (and music) as well as affective information are processed in the right hemisphere [13,14]. However, the right hemisphere stands in dynamic exchange with left-lateralized language networks via the CC [10-12], complementing and

refining prosody perception by higher level linguistic processes [40]. Accordingly, the linguistic complexity of stimuli as well as the type of task [41] could influence the lateralization. Recent evidence suggests that prosodic information processed initially in the right hemisphere is fed to domain-general emotion processing areas and integrated with semantic information, resulting in bilateral engagement [42], and that the level of left-hemispheric activations increases when the verbal complexity increases [43]. The present data indicate the relevance of the CC in affective prosody perception at the subacute stage. Future large-scale studies with other materials and more complex tasks are needed to further explore the lateralization of prosodic deficits.

Neuroanatomical overlap of music and prosodic deficits

The present lesion profiles of amusia are in line with those observed in previous studies [21,22]. Poststroke amusia was associated with right frontostriatal lesion patterns and damage of the right IFOF, similar to prosodic deficits. Importantly, this anatomical overlap was accompanied by closely related behavioral deficits in both prosody and music perception, indicating a high degree of shared neural networks underlying the two disabilities.

Both prosody and music perception involve encoding, integration, and evaluation of pitch sequences and temporal patterns in the fleeting acoustic signal. Accordingly, prosody and music may both trigger partly similar processing mechanisms along the ventral auditory stream [44], so that disconnection of the right IFOF and/or damage of its frontal termination territories would lead to comorbid prosodic and amusical impairments, as observed in the present study. Notably, a similar reasoning also applies to the basal ganglia that play a key role in rhythm perception [45] and auditory sequence processing [38,46] hence constituting another region, the damage of which can entail comorbid deficits in prosody and music perception. The close neuroanatomical and behavioral association of prosodic and musical impairment is in line with previous single case lesion studies [47], and also with prosody–music interactions in healthy adults [28].

Musical deficits showed one notable distinction from prosodic deficits. Lesion in the right AF predicted performance in both music tasks but was unrelated to prosody perception. Moreover, lesions in the left AF predicted deficits in rhythm perception. The relevance of AF for music is in line with previous findings implicating the dorsal stream in music perception [37]. Moreover, preserved right and increased left frontoparietal functional connectivity has been associated with amusia recovery [48]. Moreover, previous studies have implicated the dorsal stream in rhythm perception in music [49] but also in rhythm benefits for language [50]. The present data suggest no significant role for AF in perception of prosody, at least not at the word level tested here. Its relevance for more complex sentence-level prosody [11] remains a topic for future research.

Clinical considerations

Both aprosodia and amusia are rarely diagnosed in standard care [5] although they are relatively common poststroke deficits [5,19]. Both disorders obviously affect successful poststroke rehabilitation by hampering communication and limiting the implementation of music-based interventions and are apt to reduce patients' quality of life by affecting social interaction and psychological well-being [7].

Accurate communication between the patient and health care personnel is crucial to ensure fluent care and rehabilitation in the stroke unit. This is particularly true in severe stroke, where early and intensive inpatient rehabilitation is recommended to achieve optimal functional gains [51]. Communication may then fail to meet patients' needs of emotional support, especially at the acute stage, when patients are commonly depressed or confused. Aprosodia may, hence, sustain the patient's fright and anxiety, and impede early rehabilitation. In practice, emergency doctors and nursing staff should be made aware of the potential presence of aprosodia after right hemisphere damage.

Both aprosodia and amusia are likely to limit the positive effects of music-based rehabilitation strategies, which have recently emerged as promising and inexpensive stroke rehabilitation tools [52] included in the current American Heart Association stroke rehabilitation guideline [51]. Musical interventions, for example, those included in aphasia therapy, might require a personalized format for patients with aprosodia or amusia. Given that the processing of vocal music is relatively intact in amusia [48], singing-based rehabilitation methods seem promising in amusic [19] and aprosodic [53] patients.

When proceeding toward long-term, outpatient rehabilitation, both disorders may still significantly dilute obtainment of rehabilitation goals and reduce quality of life. Especially the loss of affective communication has been associated with reduced marital satisfaction [6] and enhanced caregiver burden [15], because the patient seemingly neglects the spouse's emotions. Due to concomitant anosognosia, common in right-hemispheric lesions, the patient him/herself may not be aware of any difficulties in emotional communication.

Amusia is likely to disrupt musical leisure activities known to mitigate depression and enhance well-being during stressful periods of life [54]. Musical activities in groups, particularly choir singing, are potential means of social integration for recovering stroke patients. Although detailed studies on the psychological effects of amusia are still pending, both aprosodia and amusia are likely to increase the risk of social isolation, reduce quality of life, and thereby subject the patient to relapsing or worsening poststroke depression, which is well known to adversely affect long-term outcome [51].

In conclusion, the present results elucidate the shared neural bases of aprosodia and amusia. In clinical practice, stroke patients with right ventral stream damage should be assessed for prosodic and musical perception deficits, preferably by a speech–language pathologist and a music therapist, due to imminent profound effects on communication and patient well-being.

ACKNOWLEDGMENTS

We express our gratitude to the staff of the Tyks Neurocenter, and the patients and their families for their participation. We thank Professors Mari Tervaniemi and Riitta Parkkola, Jani Saunavaara, and radiographers Ulla Anttalainen, Riku Luoto, and Tuija Vahtera. This study was supported by the Academy of Finland (grants 257077, 277693, 299044), Finnish Cultural Foundation (grant 191230), Orion Research Foundation, and Signe and Ane Gyllenberg Foundation.

CONFLICT OF INTEREST

The authors have no conflicts of interest to declare.

AUTHOR CONTRIBUTIONS

Aleksi J. Sihvonen: Conceptualization (equal), data curation (equal), formal analysis (equal), funding acquisition (supporting), investigation (equal), methodology (equal), visualization (equal), writing—original draft (equal), writing—review & editing (equal). **Daniela Sammler:** Conceptualization (equal), methodology (equal), supervision (equal), visualization (equal), writing—original draft (equal), writing—review & editing (equal). **Pablo Ripollés:** Conceptualization (equal), formal analysis (equal), methodology (equal), writing—review & editing (equal). **Vera Leo:** Conceptualization (equal), formal analysis (equal), investigation (equal), writing—review & editing (equal). **Antoni Rodríguez-Fornells:** Conceptualization (equal), writing—review & editing (equal). **Seppo Soinila:** Conceptualization (equal), project administration (equal), resources (equal), supervision (equal), writing—review & editing (equal). **Teppo Särkämö:** Conceptualization (equal), formal analysis (equal), funding acquisition (equal), project administration (equal), resources (equal), supervision (equal), writing—original draft (equal), writing—review & editing (equal).

DATA AVAILABILITY STATEMENT

Anonymized data supporting this study and examples of prosodic and musical stimuli can be found here: https://osf.io/st7bk/?view_only=2f1f887cb43949bca2a325f73d4b7e4d.

ORCID

Aleksi J. Sihvonen  <https://orcid.org/0000-0002-4501-7338>

REFERENCES

- Kümmerer D, Hartwigsen G, Kellmeyer P, et al. Damage to ventral and dorsal language pathways in acute aphasia. *Brain*. 2013;136(2):619-629.
- Monrad-Krohn GH. The prosodic quality of speech and its disorders: (a brief survey from a neurologist's point of view). *Acta Psychiatr Scand*. 1947;22(3-4):255-269.
- Ross ED, Monnot M. Neurology of affective prosody and its functional-anatomic organization in right hemisphere. *Brain Lang*. 2008;104(1):51-74.
- Baum SR, Pell MD. The neural bases of prosody: insights from lesion studies and neuroimaging. *Aphasiology*. 1999;13(8):581-608.
- Blake ML, Duffy JR, Tompkins CA, Myers PS. Right hemisphere syndrome is in the eye of the beholder. *Aphasiology*. 2003;17(5):423-432.
- Blonder LX, Pettigrew LC, Kryscio RJ. Emotion recognition and marital satisfaction in stroke. *J Clin Exp Neuropsychol*. 2012;34(6):634-642.
- Heilman KM. Matter of mind: a neurologist's view of brain-behavior relationships. Oxford Scholarship Online; 2009.
- Sammler D, Grosbras MH, Anwander A, Bestelmeyer PEG, Belin P. Dorsal and ventral pathways for prosody. *Curr Biol*. 2015;25(23):3079-3085.
- Frühholz S, Gschwind M, Grandjean D. Bilateral dorsal and ventral fiber pathways for the processing of affective prosody identified by probabilistic fiber tracking. *NeuroImage*. 2015;109:27-34.
- Sammler D, Kotz SA, Eckstein K, Ott DVM, Friederici AD. Prosody meets syntax: the role of the corpus callosum. *Brain*. 2010;133(9):2643-2655.
- Sammler D, Cunitz K, Gierhan SME, et al. White matter pathways for prosodic structure building: a case study. *Brain Lang*. 2018;183:1-10.
- Friederici AD, Alter K. Lateralization of auditory language functions: a dynamic dual pathway model. *Brain Lang*. 2004;89(2):267-276.
- Witteman J, Van Ijzendoorn MH, Van de Velde D, Van Heuven VJJP, Schiller NO. The nature of hemispheric specialization for linguistic and emotional prosodic perception: a meta-analysis of the lesion literature. *Neuropsychologia*. 2011;49(13):3722-3738.
- Witteman J, Van Heuven VJP, Schiller NO. Hearing feelings: a quantitative meta-analysis of the neuroimaging literature of emotional prosody perception. *Neuropsychologia*. 2012;50(12):2752-2763.
- Sheppard SM, Keator LM, Breining BL, et al. Right hemisphere ventral stream for emotional prosody identification: evidence from acute stroke. *Neurology*. 2020;94(10):e1013-e1020.
- Schirmer A, Kotz SA. Beyond the right hemisphere: brain mechanisms mediating vocal emotional processing. *Trends Cogn Sci*. 2006;10(1):24-30.
- Davis CL, Oishi K, Faria AV, et al. White matter tracts critical for recognition of sarcasm. *Neurocase*. 2016;22(1):22-29.
- Catani M. From hodology to function. *Brain*. 2007;130(3):602-605.
- Sihvonen AJ, Särkämö T, Rodríguez-Fornells A, Ripollés P, Münte TF, Soinila S. Neural architectures of music – Insights from acquired amusia. *Neurosci Biobehav Rev*. 2019;107:104-114.
- Stewart L, Von Kriegstein K, Warren JD, Griffiths TD. Music and the brain: Disorders of musical listening. *Brain*. 2006;129(10):2533-2553.
- Sihvonen AJ, Ripollés P, Rodríguez-Fornells A, Soinila S, Särkämö T. Revisiting the neural basis of acquired amusia: lesion patterns and structural changes underlying amusia recovery. *Front Neurosci*. 2017;11:426.
- Sihvonen AJ, Ripollés P, Leo V, Rodríguez-Fornells A, Soinila S, Särkämö T. Neural basis of acquired amusia and its recovery after stroke. *J Neurosci*. 2016;36(34):8872-8881.
- Sihvonen AJ, Ripollés P, Särkämö T, et al. Tracting the neural basis of music: deficient structural connectivity underlying acquired amusia. *Cortex*. 2017;97:255-273.
- Zhang Y, Kimberg DY, Coslett HB, Schwartz MF, Wang Z. Multivariate lesion-symptom mapping using support vector regression. *Hum Brain Mapp*. 2014;35(12):5861-5876.
- Nakhutina L, Borod JC, Zgaljardic DJ. Posed prosodic emotional expression in unilateral stroke patients: recovery, lesion location, and emotional perception. *Arch Clin Neuropsychol*. 2006;21(1):1-13.
- Pihan H, Altenmüller E, Hertrich I, Ackermann H. Cortical activation patterns of affective speech processing depend on concurrent demands on the subvocal rehearsal system. A DC-potential study. *Brain*. 2000;123(11):2338-2349.
- Pihan H, Altenmüller E, Ackermann H. The cortical processing of perceived emotion: a DC-potential study on affective speech prosody. *NeuroReport*. 1997;8(3):623-627.

28. Hausen M, Torppa R, Salmela VR, Vainio M, Särkämö T. Music and speech prosody: a common rhythm. *Front Psychol*. 2013;4:566.
29. Leinonen L, Hiltunen T, Linnankoski I, Laakso M-L. Expression of emotional-motivational connotations with a one-word utterance. *J Acoust Soc Am*. 1997;102(3):1853-1863.
30. Särkämö T, Tervaniemi M, Soinila S, et al. Amusia and cognitive deficits after stroke: is there a relationship. *Ann N Y Acad Sci*. 2009;1169:441-445.
31. Peretz I, Champod AS, Hyde K. Varieties of musical disorders: the montreal battery of evaluation of amusia. *Ann N Y Acad Sci*. 2003;999:58-75.
32. DeMarco AT, Turkeltaub PE. A multivariate lesion symptom mapping toolbox and examination of lesion-volume biases and correction methods in lesion-symptom mapping. *Hum Brain Mapp*. 2018;39(11):4169-4182.
33. Colby JB, Soderberg L, Lebel C, Dinov ID, Thompson PM, Sowell ER. Along-tract statistics allow for enhanced tractography analysis. *NeuroImage*. 2012;59(4):3227-3242.
34. Catani M, Mesulam M. The arcuate fasciculus and the disconnection theme in language and aphasia: history and current state. *Cortex*. 2008;44(8):953-961.
35. Hau J, Sarubbo S, Perchey G, et al. Cortical terminations of the inferior fronto-occipital and uncinate fasciculi: anatomical stem-based virtual dissection. *Front Neuroanat*. 2016;10:58.
36. Belyk M, Brown S. Perception of affective and linguistic prosody: an ALE meta-analysis of neuroimaging studies. *Soc Cogn Affect Neurosci*. 2013;9(9):1395-1403.
37. Griffiths TD. The neural processing of complex sounds. *Ann N Y Acad Sci*. 2001;930:133-142.
38. Kotz SA, Hasting AS, Paulmann S. On the orbito-striatal interface in (acoustic) emotional processing. *Evolution of Emotional Communication*. Oxford University Press; 2013:229-240.
39. Blonder LX, Gur RE, Gur RC. The effects of right and left hemiparkinsonism on prosody. *Brain Lang*. 1989;36(2):193-207.
40. van der Burght CL, Goucha T, Friederici AD, Kreitewolf J, Hartwigsen G. Intonation guides sentence processing in the left inferior frontal gyrus. *Cortex*. 2019;117:122-134.
41. Kotz SA, Meyer M, Paulmann S. Lateralization of emotional prosody in the brain: an overview and synopsis on the impact of study design. *Prog Brain Res*. 2006;156:285-294.
42. Seydell-Greenwald A, Chambers CE, Ferrara K, Newport EL. What you say versus how you say it: comparing sentence comprehension and emotional prosody processing using fMRI. *NeuroImage*. 2020;209:116509.
43. Mitchell RLC, Ross ED. fMRI evidence for the effect of verbal complexity on lateralisation of the neural response associated with decoding prosodic emotion. *Neuropsychologia*. 2008;46(12):2880-2887.
44. Rauschecker JP, Scott SK. Maps and streams in the auditory cortex: nonhuman primates illuminate human speech processing. *Nat Neurosci*. 2009;12(6):718-724.
45. Grahn JA, Brett M. Impairment of beat-based rhythm discrimination in Parkinson's disease. *Cortex*. 2009;45(1):54-61.
46. Frühholz S, Trost W, Kotz SA. The sound of emotions-Towards a unifying neural network perspective of affective sound processing. *Neurosci Biobehav Rev*. 2016;68:96-110.
47. Patel AD, Peretz I, Tramo M, Labreque R. Processing prosodic and musical patterns: a neuropsychological investigation. *Brain Lang*. 1998;61(1):123-144.
48. Sihvonen AJ, Särkämö T, Ripollés P, et al. Functional neural changes associated with acquired amusia across different stages of recovery after stroke. *Sci Rep*. 2017;7(1):11390.
49. Vaquero L, Ramos-Escobar N, Cucurell D, et al. Arcuate fasciculus architecture is associated with individual differences in pre-attentive detection of unpredicted music changes. *NeuroImage*. 2021;229:117759.
50. Assaneo MF, Ripollés P, Orpella J, Lin WM, de Diego-Balaguer R, Poeppel D. Spontaneous synchronization to speech reveals neural mechanisms facilitating language learning. *Nat Neurosci*. 2019;22(4):627-632.
51. Winstein CJ, Stein J, Arena R, et al. Guidelines for adult stroke rehabilitation and recovery: a guideline for healthcare professionals from the American Heart Association/American Stroke Association. *Stroke*. 2016;47(6):e98-e169.
52. Sihvonen AJ, Särkämö T, Leo V, Tervaniemi M, Altenmüller E, Soinila S. Music-based interventions in neurological rehabilitation. *Lancet Neurol*. 2017;16(8):648-660.
53. Leon SA, Rodriguez AD. Aprosodia and its treatment. *Perspect Neurophysiol Neurogenic Speech Lang Disord*. 2008;18(2):66-72.
54. Mas-Herrero E, Singer N, Ferreri L, McPhee M, Zatorre RJ & Ripollés P Rock 'n' Roll but not Sex or Drugs: Music is negatively correlated to depressive symptoms during the COVID-19 pandemic via reward-related mechanisms. *PsyArXiv [Internet]*. 2020; December 2:1-57. Available from <https://psyarxiv.com/x5upn/>. Accessed February 5, 2021.

How to cite this article: Sihvonen AJ, Sammler D, Ripollés P, et al. Right ventral stream damage underlies both poststroke aprosodia and amusia. *Eur J Neurol*. 2022;29:873-882. <https://doi.org/10.1111/ene.15148>