Tracting the neural basis of music: Deficient structural connectivity underlying acquired amusia

Article *in* Cortex · October 2017

DOI: 10.1016/j.cortex.2017.09.028

8 authors, including:

Aleksi Sihvonen
University of Helsinki

Pablo Ripollés
New York University

Teppo Särkämö
University of Helsinki

Vera Leo
University of Helsinki

ARTICLE IN PRESS

cortex xxx (2017) 1–19

Available online at www.sciencedirect.com

ScienceDirect

Journal homepage: www.elsevier.com/locate/cortex

Special issue: Clinical neuroanatomy

Tracting the neural basis of music: Deficient structural connectivity underlying acquired amusia

Aleksi J. Sihvonen [a,b,*], *Pablo Ripollés* [c,d,e], *Teppo Särkämö* [b], *Vera Leo* [b], *Antoni Rodríguez-Fornells* [c,d], *Jani Saunavaara* [f], *Riitta Parkkola* [g] *and Seppo Soinila* [h,i]

[a] *Faculty of Medicine, University of Turku, Turku, Finland*
[b] *Cognitive Brain Research Unit, Faculty of Medicine, University of Helsinki, Helsinki, Finland*
[c] *Cognition and Brain Plasticity Group, Bellvitge Biomedical Research Institute (IDIBELL), L'Hospitalet de Llobregat, Barcelona, Spain*
[d] *Department of Basic Psychology, University of Barcelona, Barcelona, Spain*
[e] *Poeppel Lab, Department of Psychology, New York University, NY, USA*
[f] *Department of Medical Physics, Turku University Hospital, Turku, Finland*
[g] *Department of Radiology, Turku University and Turku University Hospital, Turku, Finland*
[h] *Division of Clinical Neurosciences, Turku University Hospital, Turku, Finland*
[i] *Department of Neurology, University of Turku, Turku, Finland*

ARTICLE INFO

Article history:
Received 23 March 2017
Reviewed 23 May 2017
Revised 8 June 2017
Accepted 29 September 2017
Published online xxx

Keywords:
Amusia
Music
Stroke

ABSTRACT

Acquired amusia provides a unique opportunity to investigate the fundamental neural architectures of musical processing due to the transition from a functioning to defective music processing system. Yet, the white matter (WM) deficits in amusia remain systematically unexplored. To evaluate which WM structures form the neural basis for acquired amusia and its recovery, we studied 42 stroke patients longitudinally at acute, 3-month, and 6-month post-stroke stages using DTI [tract-based spatial statistics (TBSS) and deterministic tractography (DT)] and the Scale and Rhythm subtests of the Montreal Battery of Evaluation of Amusia (MBEA). Non-recovered amusia was associated with structural damage and subsequent degeneration in multiple WM tracts including the right inferior fronto-occipital fasciculus (IFOF), arcuate fasciculus (AF), inferior longitudinal fasciculus (ILF), uncinate fasciculus (UF), and frontal aslant tract (FAT), as well as in the corpus callosum (CC) and its posterior part (tapetum). In a linear regression analysis, the volume of

Abbreviations: AF, arcuate fasciculus; ANOVA, analysis of variance; CC, corpus callosum; DT, deterministic tractography; DTI, diffusion tensor imaging; FA, fractional anisotropy; FAT, frontal aslant tract; FWE, familywise error rate; GMV, grey matter volume; IFG, inferior frontal gyrus; IFOF, inferior fronto-occipital fasciculus; IC, internal capsule; ILF, inferior longitudinal fasciculus; IPL, inferior parietal lobule; MBEA, Montreal battery of evaluation of amusia; MCA, middle cerebral artery; MD, mean diffusivity; MTG, middle temporal gyrus; NA, non-amusic; NRA, non-recovered amusic; pNA, non-pitch-amusic; pNRA, non-recovered pitch-amusic; pRA, recovered pitch-amusic; pre-SMA, presupplementary motor area; RD, radial diffusivity; rNA, non-rhythm-amusic; rNRA, non-recovered rhythm-amusic; RA, recovered amusic; RHD, right hemisphere damage; ROI, region of interest; rRA, recovered rhythm-amusic; SLF, superior longitudinal fasciculus; SMA, supplementary motor area; STG, superior temporal gyrus; TBSS, tract-based spatial statistics; UF, uncinate fasciculus; WM, white matter.

* *Corresponding author*. Cognitive Brain Research Unit, Faculty of Medicine, University of Helsinki Siltavuorenpenger, University of Helsinki, 1B, FI-00014, Finland.
E-mail address: ajsihv@utu.fi (A.J. Sihvonen).
https://doi.org/10.1016/j.cortex.2017.09.028

Please cite this article in press as: Sihvonen, A. J., et al., Tracting the neural basis of music: Deficient structural connectivity underlying acquired amusia, Cortex (2017), https://doi.org/10.1016/j.cortex.2017.09.028

Tractography
Tract-based spatial statistics

the right IFOF was the main predictor of MBEA performance across time. Overall, our results provide a comprehensive picture of the large-scale deficits in intra- and interhemispheric structural connectivity underlying amusia, and conversely highlight which pathways are crucial for normal music perception.

1. Introduction

The ability to perceive, enjoy, and produce music is a fundamental element of human cognition. Studies with healthy subjects have revealed a widely distributed bilateral neural network activated by musical stimuli (Koelsch, 2014; Zatorre & Salimpoor, 2013). However, studies of persons with musical deficits are essentially needed to determine the critical structures required by musical processing in the brain (Rorden & Karnath, 2004).

Amusia, caused by either abnormal brain development (congenital amusia) or brain damage (acquired amusia), is a neurological disorder characterized mainly by inability to perceive fine-grained pitch changes. In addition, the processing of musical rhythm, timbre, memory, and emotions can also be affected (Marin, Gingras, & Stewart, 2012; Stewart, von Kriegstein, Warren, & Griffiths, 2006). While only 2–4% of the population is affected by congenital amusia (Henry & McAuley, 2010; Kalmus & Fry, 1980), the prevalence of acquired amusia after stroke in the middle cerebral artery (MCA) territory is substantially higher, reportedly ranging between 35% and 69% (Ayotte, Peretz, Rousseau, Bard, & Bojanowski, 2000; Schuppert, Münte, Wieringa, & Altenmüller, 2000; Sihvonen et al., 2016; Särkämö et al., 2009). Notably, congenital amusia is a life-long condition and therefore reflects not only impaired music perception, but also a developmental deficit in acquiring musical syntax and tonal representations or lack of exposure to music (Stewart, 2008). In contrast, acquired amusia is characterized by a clear-cut shift from a normal to deficient function of the music processing system caused by a brain lesion. This creates a naturalistic opportunity to examine and pin down the brain areas that are crucial for music perception.

Recently, we reported damage to the right superior temporal gyrus (STG), Heschl's gyrus (HG), middle temporal gyrus (MTG), insula, and putamen to be the crucial neural substrate for acquired amusia after stroke (Sihvonen et al., 2016). In 6-month follow-up, persistent (non-recovering) amusia was associated with grey matter volume (GMV) decrease in the right STG and MTG, and white matter (WM) volume decrease in the MTG. We speculated that lesions linked to acquired amusia damage the WM pathways connecting the right frontal and temporal regions, which possibly leads to neural degeneration and consequent GMV decrease. Congenital amusics have reduced WM in the right inferior frontal gyrus (IFG; Hyde, Zatorre, Griffiths, Lerch, & Peretz, 2006) accompanied by GM anomalies in the same region (Albouy et al., 2013; Hyde et al., 2006, 2007) and in the right STG (Albouy et al., 2013; Hyde et al., 2007) as well as reduced frontotemporal functional (Albouy et al., 2013) and resting-state (Leveque et al., 2016) connectivity.

While the abnormalities in the structure, function, and connectivity of the right superior temporal and the inferior frontal brain areas are thought to be a plausible mechanism underlying congenital amusia, there is still scarce and insufficient direct evidence for structural WM abnormalities in amusia derived from diffusion tensor imaging (DTI). There are only two previous tractography studies on congenital amusia (Chen et al., 2015; Loui, Alsop, & Schlaug, 2009) and none on acquired amusia. In addition, both studies on congenital amusia investigated only one tract, the arcuate fasciculus (AF), and yielded conflicting findings: While Loui et al. (2009) compared 10 congenital amusics to 10 healthy controls and found decreased volume of the right AF, Chen et al. (2015) compared 26 amusics to 26 healthy subjects and found no significant differences between the groups. In addition, congenital amusics have been shown to have reduced global connectivity (Zhao et al., 2016).

Frontal and temporal regions are connected not only by the AF (Fig. 1). As various other WM pathways interconnect these areas directly or through other pathways, musical processing might be mediated by other WM tracts as well. For example, the inferior fronto-occipital fasciculus (IFOF) connects occipital, posterior temporal, and frontal regions (Catani, Howard, Pajevic, & Jones, 2002; Kier, Staib, Davis, & Bronen, 2004; Martino, Brogna, Robles, Vergani, & Duffau, 2010; Sarubbo, De Benedictis, Maldonado, Basso, & Duffau, 2013; Turken & Dronkers, 2011). In addition, the uncinate fasciculus (UF) connects the temporal pole with inferior frontal areas (Kier et al., 2004). Indeed, subjects with absolute pitch have increased WM integrity in both of these tracts in the right hemisphere (Dohn et al., 2015) as well as in the inferior longitudinal fasciculus (ILF), which connects the temporal pole with the occipital cortex (Catani et al., 2002). Furthermore, increased WM integrity in the right IFOF has been related to musical synesthesia (Zamm, Schlaug, Eagleman, & Loui, 2013). In addition to evaluating the connections between the frontal and temporal regions, evaluation of the interhemispheric connectivity [e.g., corpus callosum (CC) and its segments] in amusia would be important as in congenital amusia, the functional connectivity between the auditory cortices in both hemispheres has been shown to be altered (Hyde, Zatorre, & Peretz, 2011). In addition, the frontal aslant tract (FAT), which connects inferior frontal and motor cortical areas and has an established role in language processing (Vassal et al., 2016) and working memory (Rizio & Diaz, 2016), could also contribute to music processing given the importance of these structures for music-syntactic and rhythm processing.

Another line of evidence to support involvement of various WM pathways in music processing comes from studies of long-term musical training. Compared to non-musicians,

Please cite this article in press as: Sihvonen, A. J., et al., Tracting the neural basis of music: Deficient structural connectivity underlying acquired amusia, Cortex (2017), https://doi.org/10.1016/j.cortex.2017.09.028

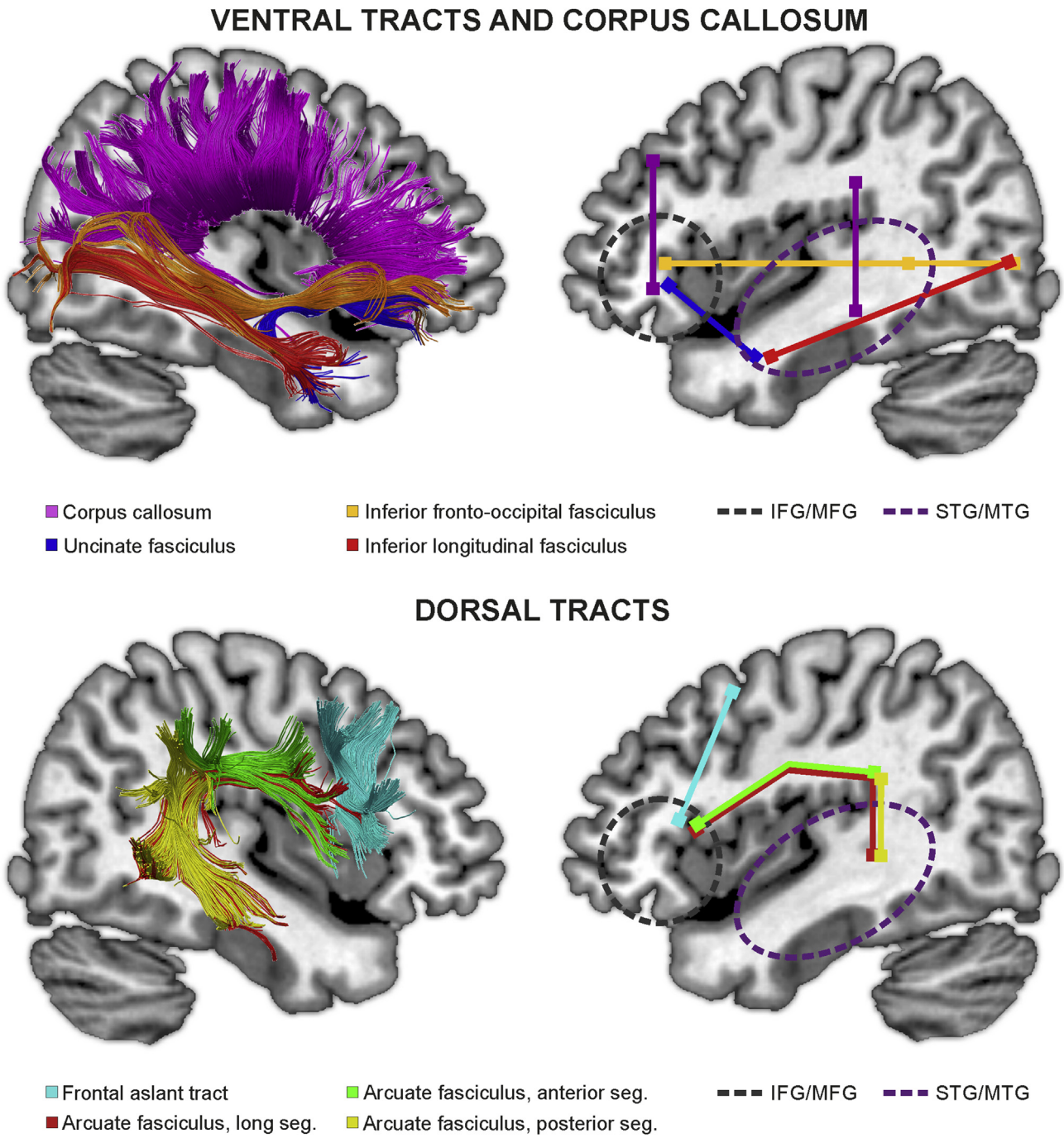

Fig. 1 – A visualization and schematic representation of the white matter pathways included in the tractography. IFG = Inferior frontal gyrus, MFG = Middle frontal gyrus, MTG = Middle temporal gyrus, STG = superior temporal gyrus.

musicians show WM plastic changes [e.g., tract volume, fractional anisotropy (FA)] in the CC (Bengtsson et al., 2005; Schlaug, Jancke, Huang, Staiger, & Steinmetz, 1995; Schmithorst & Wilke, 2002), the pyramidal tracts (Bengtsson et al., 2005; Han et al., 2009; Ruber, Lindenberg, & Schlaug, 2015; Schmithorst & Wilke, 2002), the AF/superior longitudinal fasciculus (SLF; Bengtsson et al., 2005; Halwani, Loui, Ruber, & Schlaug, 2011; Oechslin, Imfeld, Loenneker, Meyer, & Jancke, 2010), the IFOF (Schmithorst & Wilke, 2002), and in the cerebellar tracts (Abdul-Kareem et al., 2011; Schmithorst & Wilke, 2002). Given the complexity and diverse nature of musical training, these structural neuroplastic changes naturally reflect the interaction of many auditory-perceptual, motor, tactile, and cognitive functions.

Another important aspect is that music processing in the brain is not limited to temporal and frontal areas. Functional neuroimaging studies show that music processing and perception involve a large-scale network comprising bilateral temporal, frontal, parietal, and subcortical regions (Alluri et al., 2012; Brattico et al., 2011; Schmithorst, 2005). The

music network also extends to motor regions of the brain to recruit presupplementary motor area (pre-SMA), supplementary motor area (SMA), and cerebellum for musical rhythm processing (Chen, Penhune, & Zatorre, 2008). Moreover, both music-related ventral (i.e., extreme capsule) and dorsal streams in the right hemisphere have been suggested to act parallel in transferring musical auditory information between the temporal, inferior parietal, and inferior frontal regions (Loui, 2015; Musso et al., 2015; Rauschecker, 2014; Sammler, Grosbras, Anwander, Bestelmeyer, & Belin, 2015; Zatorre, Belin, & Penhune, 2002). Similarly to aphasia, whereby damage to dorsal language-related pathways are associated with productive impairments and damage to ventral language-related pathways with comprehension deficits (Kummerer et al., 2013), music production and perception could rely on different streams (Loui, 2015; Loui, Guenther, Mathys, & Schlaug, 2008; Sammler et al., 2015). Taken together, these findings suggest that the critical pathway to be compromised in music perception deficits (i.e., amusia) could also be the right ventral pathway. To uncover the brain regions and neural pathways that are crucial for music perception, systematic and longitudinal research on the neural basis of acquired amusia and its recovery is still needed, specifically in order to map different tracts connecting the key musical cortical and subcortical areas. Clinically, this information would also be important for establishing a more accurate diagnosis and prognosis of amusia as well as for rehabilitation planning.

Diffusion MRI allows calculation of tensors from which many different indices of WM structure can be extracted. FA reflects the variability in diffusion in different directions (anisotropy) and is highly sensitive to microstructural changes. Mean diffusivity (MD) is a directionally averaged, inverse measure of the membrane density, and it is sensitive to cellularity, edema, and necrosis (Alexander et al., 2011). Radial diffusivity (RD) describes the diffusivity perpendicular to the axon and is influenced by changes in axonal diameter or density. Importantly, the comparison of different DTI indices in the same focus gives more specific information about the type of change in WM. For example, aphasics have lower FA values and higher MD and RD values than patients without post-stroke aphasia (Ivanova et al., 2016). Furthermore, after stroke affecting a motor pathway, the axonal damage and poor motor outcome have been linked to decreased FA as well as increased MD and RD (Yu et al., 2009). In addition, increased RD (Harsan et al., 2006; Song et al., 2002, 2005) and decreased FA (Harsan et al., 2006) have been associated with dys- and demyelination.

The information obtained from DTI can be used to delineate and compare WM tracts (Basser, Pajevic, Pierpaoli, Duda, & Aldroubi, 2000; Conturo et al., 1999). One of the most common algorithms is deterministic tractography (DT), whereby different voxels are connected through their preferred diffusion directions to form one projection to represent a WM tract (Conturo et al., 1999). The statistical information on the visualized tracts can then be analyzed. A more recent method to evaluate WM structures is Tract-Based Spatial Statistics (TBSS), which allows voxel-wise statistical analysis of the DTI data. Using non-linear registration and alignment-invariant tract representation, TBSS tries to improve several issues of group analysis, such as image alignment and the amount of spatial smoothing used (Smith et al., 2006).

In the present study, we utilized both TBSS and DT to examine systematically the quantitative changes in WM pathways in patients with acquired amusia after stroke. We also examined which changes in the tracts are associated with the recovery of acquired amusia. DT and TBSS work as complementary methods with two different spatial resolutions (tract and voxel level). To our best knowledge, this is the first study to combine TBSS and DT in evaluating amusia. Based on our previous findings, the scarcity of evidence on tract deficits in amusia, and on the wide-spread involvement of brain regions in music processing in healthy subjects, we chose to comprehensively evaluate all WM pathways connected to the STG and MTG, and inferior and medial frontal gyri, aiming to uncover the tract changes linked to amusia and its recovery after stroke (see Fig. 1).

2. Materials and methods

2.1. Subjects and study design

Fifty subjects were recruited between March 2013 and December 2015 from the Department of Clinical Neurosciences of the Turku University Hospital (Tyks) after being admitted to the hospital for treatment of stroke. Inclusion criteria were: (1) an acute ischemic stroke or intracerebral hemorrhage in the left or right hemisphere, (2) no prior neurological or psychiatric disease, (3) no drug or alcohol abuse, (4) no hearing deficit, (5) ≤80 years of age, (6) home in the Southwest Finland, (7) Finnish-speaking, and (8) sufficient co-operation. All patients were right-handed and enrolled in a larger music listening intervention study. All subjects signed an informed consent, and received standard stroke treatment and rehabilitation. The study was approved by the Ethics Committee of the Hospital District of Southwest Finland, and it was carried out conforming to Declaration of Helsinki. All subjects underwent a behavioral assessment and an MRI within 3 weeks of the stroke onset and during the follow-up at 3 and 6 months post-stroke. Out of the 50 subjects recruited, seven dropped out. In addition, one patient could not be assessed for amusia in the acute phase. Therefore, 42 subjects with complete follow-up data were entered in the final analysis. The clinical and demographic background of the patients is presented in Tables 1 and 2.

2.2. Assessment of amusia

The music perception of the patients was evaluated with a shortened version (Särkämö et al., 2009) of the Montreal Battery of Evaluation of Amusia (MBEA; Peretz, Champod, & Hyde, 2003) in the acute stage (<3 weeks post-stroke) and at the 3-month and 6-month post-stroke stage as a part of a larger neuropsychological testing battery. The stimuli were presented by using a laptop and headphones.

Following our previous studies (Sihvonen et al., 2016; Särkämö et al., 2009) and the established cut-off values of the original MBEA (Peretz et al., 2003), we classified patients with the MBEA Scale and Rhythm average score < 75% as amusic

Table 1 – Demographic and musical background of the patients ($n = 42$).

Patient ID	Group amusia	Group pitch amusia	Group rhythm amusia	Gender	Age	Education (years)	Formal music training[a]	Other music training[a]	Active music listening[b]	Passive music listening[b]	Musical reward[c]
3	NA	pNA	rNA	f	59	15	0	0	1	7	66
5	NA	pNA	rNA	m	57	13	0	2	5	7	87
9	NA	pNA	rNA	f	44	17	0	0	5	7	75
10	NA	pNA	rRA	m	42	17	0	5	3	6	64
11	NA	pNA	rNA	f	57	14	0	5	1	7	59
13	NA	pNA	rNA	f	62	15,5	5	2	7	7	92
14	NA	pNA	rNA	m	27	13	0	0	6	7	60
15	NA	pNA	rRA	f	65	23	0	0	6	7	81
17	NA	pNA	rNRA	f	70	14	2	5	5	3	67
18	NA	pNA	rRA	m	56	24	0	3	7	1	77
19	NA	pNA	rNA	f	25	17	0	0	7	7	88
20	NA	pNA	rNRA	m	77	12	5	5	6	7	91
21	NA	pNA	rNA	m	56	17,5	0	3	6	7	87
4	NA	pNA	rNA	m	55	13	0	0	2	7	79
6	NA	pNA	rNRA	f	73	20	0	0	–	–	–
7	NA	pNA	rNRA	m	47	12	0	5	3	6	54
8	NA	pNA	rRA	f	70	10	0	0	7	7	48
12	RA	pRA	rNRA	m	76	8	0	5	4	4	86,96
16	RA	pRA	rNRA	f	76	22	0	0	3	3	58
25	RA	pNA	rRA	f	24	16	2	2	6	7	76
27	RA	pRA	rNRA	m	63	12	–	–	7	7	90
35	RA	pNA	rNRA	m	57	10	0	0	5	7	82
42	RA	pNA	rRA	m	54	17	4	5	6	7	82
24	RA	pRA	rRA	m	60	13	0	5	3	7	90
31	RA	pNA	rRA	m	53	11	0	0	7	5	76
32	RA	pNRA	rNRA	m	71	12	0	0	4	5	69
38	RA	pRA	rRA	m	46	11	0	0	1	7	68
1	NRA	pNA	rNRA	f	39	13	0	0	6	7	93
2	NRA	pNRA	rNA	m	53	15	0	0	5	7	76
22	NRA	pNRA	rNRA	m	72	11	0	0	3	4	70
23	NRA	pNRA	rNRA	m	66	8	0	0	6	7	77
26	NRA	pNRA	rNRA	m	52	14	0	3	7	7	94
28	NRA	pNRA	rNRA	m	31	16	0	0	3	7	58
29	NRA	pNRA	rRA	f	77	9	0	0	3	7	82
30	NRA	pNRA	rNRA	m	48	17	0	5	7	7	90
33	NRA	pNRA	rNRA	f	54	11	0	0	1	2	70
34	NRA	pNRA	rNRA	f	73	7	0	0	7	6	89
36	NRA	pRA	rRA	f	71	13,5	0	0	1	7	69
37	NRA	pNRA	rNRA	m	39	11	0	0	2	7	80
39	NRA	pRA	rNRA	f	62	11	0	0	5	7	82
40	NRA	pNRA	rNRA	m	47	16	0	0	4	7	77
41	NRA	pNRA	rNRA	f	69	7	0	0	7	7	84
		Amusia overall		.231 (χ^2)	.909 (K)	.026 (K)	.197 (K)	.075 (K)	.908 (K)	.552 (K)	.449 (K)
		Pitch amusia		.540 (χ^2)	.167 (K)	.042 (K)	.092 (K)	.164 (K)	.216 (K)	.882 (K)	.847 (K)
		Rhythm amusia		.805 (χ^2)	.193 (K)	.074 (K)	.823 (K)	.788 (K)	.966 (K)	.075 (K9)	.542 (K)

χ^2 = chi-square test, K = Kruskal–Wallis test, NA = Non-amusic, NRA = Non-recovered amusic, pNA = Non-pitch-amusic, pNRA = Non-recovered pitch-amusic, pRA = recovered pitch-amusic, RA = recovered amusic, rNA = Non-rhythm-amusic, rNRA = Non-recovered rhythm-amusic, rRA = recovered rhythm-amusic.

[a] Numbers denote values on a Likert scale where 0 = no, 1 = less than 1 year, 2 = 1–3 years, 3 = 4–6 years, 4 = 7–10 years, and 5 = more than 10 years of training/playing.

[b] Numbers denote values on a Likert scale with a range 0 (does never) to 7 (does daily).

[c] Classification based on Barcelona Music Reward Questionnaire to reflect pre-stroke musical reward.

[amusic $N = 25$, non-amusic (NA) $N = 17$]. We further subdivided the amusic patients to recovered amusics (RAs; $N = 10$), who were tested as NA at the 6-month stage according to the initial cut-off values, and to non-recovered amusics (NRAs; $N = 15$). To evaluate pitch and rhythm amusia separately, similar principle was also applied to the Scale and Rhythm subtest scores. Patients with Scale subtest score <73% in the acute stage were defined as pitch-amusic [$N = 20$, non-pitch-amusic (pNA) $N = 22$]. At the 6-month stage, seven patients were classified as recovered pitch-amusics (pRA) and 13 as non-recovered pitch-amusics (pNRA). When Rhythm subtest was evaluated with cut-off score <77%, the figures were: 10 non-rhythm-amusics (rNA), 21 non-recovered rhythm-amusics (rNRA), and 11 recovered rhythm-amusics (rRA).

Please cite this article in press as: Sihvonen, A. J., et al., Tracting the neural basis of music: Deficient structural connectivity underlying acquired amusia, Cortex (2017), https://doi.org/10.1016/j.cortex.2017.09.028

Table 2 – Clinical characteristics of the patients ($n = 42$).

Patient ID	Group amusia	Group pitch amusia	Group rhythm amusia	Aphasia[a]	MBEA total score %	MBEA scale score %	MBEA rhythm score %	Visual neglect[b]	Lesion laterality	Lesion volume in cm^3
3	NA	pNA	rNA	no	85	83,33	86,67	no	left	35,679
5	NA	pNA	rNA	yes	83,33	86,67	80	no	left	35,798
9	NA	pNA	rNA	no	90	96,67	83,33	no	left	23,026
10	NA	pNA	rRA	yes	86,67	100	73,33	no	left	4,372
11	NA	pNA	rNA	no	85	83,33	86,67	no	left	1,461
13	NA	pNA	rNA	no	88,33	93,33	83,33	no	left	25,322
14	NA	pNA	rNA	yes	80	80	80	no	left	10,908
15	NA	pNA	rRA	yes	80	93,33	66,67	no	left	8,352
17	NA	pNA	rNRA	yes	75	83,33	66,67	no	left	3,037
18	NA	pNA	rRA	yes	81,67	90	73,33	no	left	178,46
19	NA	pNA	rNA	yes	91,67	100	83,33	no	left	88,863
20	NA	pNA	rNRA	yes	81,67	90	73,33	yes	left	10,869
21	NA	pNA	rNA	no	88,34	93,33	83,33	no	left	8,446
4	NA	pNA	rNA	no	80	80	80	yes	right	64,26
6	NA	pNA	rNRA	yes	78,33	86,67	70	no	right	31,622
7	NA	pNA	rNRA	no	86,67	96,67	76,67	no	right	45,296
8	NA	pNA	rRA	no	81,67	86,67	76,67	no	right	111,326
12	RA	pRA	rNRA	yes	63,33	56,67	70	no	left	17,004
16	RA	pRA	rNRA	yes	63,33	60	66,67	no	left	23,023
25	RA	pNA	rRA	yes	71,67	86,67	56,67	no	left	12,809
27	RA	pRA	rNRA	yes	63,33	66,67	60	no	left	82,795
35	RA	pNA	rNRA	yes	65	90	40	no	left	72,474
42	RA	pNA	rRA	yes	70	83,33	56,67	no	left	2,237
24	RA	pRA	rRA	no	68,34	60	76,67	yes	right	54,155
31	RA	pNA	rRA	yes	66,67	90	43,33	no	right	37,439
32	RA	pNRA	rNRA	yes	48,34	50	46,67	yes	right	71,72
38	RA	pRA	rRA	yes	55	53,33	56,67	yes	right	152,299
1	NRA	pNA	rNRA	yes	73,33	80	66,67	no	left	5,204
2	NRA	pNRA	rNA	yes	63,33	46,67	80	no	left	9,614
22	NRA	pNRA	rNRA	yes	51,67	46,67	56,67	–	right	150,559
23	NRA	pNRA	rNRA	no	61,67	66,67	56,67	no	right	61,313
26	NRA	pNRA	rNRA	yes	51,67	50	53,33	–	right	124,245
28	NRA	pNRA	rNRA	no	56,67	56,67	56,67	no	right	40,226
29	NRA	pNRA	rRA	no	56,67	50	63,33	no	right	11,752
30	NRA	pNRA	rNRA	no	50	50	50	yes	right	119,092
33	NRA	pNRA	rNRA	no	48,33	53,33	43,33	no	right	117,768
34	NRA	pNRA	rNRA	yes	55	56,67	53,33	yes	right	20,012
36	NRA	pRA	rRA	no	71,67	70	73,33	no	right	32,609
37	NRA	pNRA	rNRA	no	51,67	43,33	60	yes	right	187,292
39	NRA	pRA	rNRA	yes	46,67	46,67	46,67	yes	right	99,181
40	NRA	pNRA	rNRA	yes	46,67	46,67	46,67	yes	right	102,966
41	NRA	pNRA	rNRA	yes	46,67	46,67	46,67	yes	right	24,139
		Amusia overall		.111 (χ^2)	.000 (K)	.000 (K)	.000 (K)	.110 (χ^2)	.001 (χ^2)	.166 (K)
		Pitch amusia		.721 (χ^2)	.000 (K)	.000 (K)	.000 (K)	.014 (χ^2)	.000 (χ^2)	.031 (K)
		Rhythm amusia		.240 (χ^2)	.000 (K)	.000 (K)	.000 (K)	.132 (χ^2)	.012 (χ^2)	.179 (K)

χ^2 = chi-square test, K = Kruskal–Wallis test, MBEA = Montreal Battery of Evaluation of Amusia, NA = Non-amusic, NRA = Non-recovered amusic, pNA = Non-pitch-amusic, pNRA = Non-recovered pitch-amusic, pRA = recovered pitch-amusic, RA = recovered amusic, rNA = Non-rhythm-amusic, rNRA = Non-recovered rhythm-amusic, rRA = recovered rhythm-amusic.

[a] Classification based on the Boston Diagnostic Aphasia Examination – Aphasia Severity Rating Scale.

[b] Classification based on the Lateralized Inattention Index of the Balloons Test.

2.3. *MRI data acquisition, processing and TBSS analysis*

Patients were scanned using a standard 12-channel head matrix coil on a 3T Siemens Magnetom Verio scanner at the Medical Imaging Centre of Southwest Finland. Diffusion MRI scans (TR = 11700 ms, TE = 88 ms, acquisition matrix = 112 × 112, 66 axial slices, voxel size = 2.0 × 2.0 × 2.0 mm) were acquired with one non-diffusion weighted volume and 64 diffusion weighted volumes (b-values of 1000 s/mm^2).

Voxel-wise statistical analysis of the FA, MD, and RD data was carried out using TBSS (Smith et al., 2006), part of FMRIB Software Library (University of Oxford, FSL v5.0.8, www.fmrib.ox.ac.uk/fsl; Smith et al., 2004). Diffusion data processing started by correcting eddy current distortions and head motion. Subsequently, to provide more accurate estimate of diffusion tensor orientations, the gradient matrix was rotated using FSL's fdt rotate bvecs (Leemans & Jones, 2009). Following this, brain extraction was performed using the Brain

Extraction Tool (Smith, 2002). Analysis continued with the reconstruction of the diffusion tensors using the linear least-squares algorithm included in Diffusion Toolkit 0.6.2.2 (Ruopeng Wang, Van J. Wedeen, trackvis.org/dtk, Martinos Center for Biomedical Imaging, Massachusetts General Hospital). Finally, FA, MD and RD maps for each patient and session were calculated using the eigenvalues extracted from the diffusion tensors. All subjects' FA data were then aligned into a common space using the nonlinear registration tool FNIRT (Andersson, Jenkison, & Smith, 2007a, 2007b), which uses a b-spline representation of the registration warp field (Rueckert et al., 1999). In order to improve the normalization, using Cost Function Masking, masks of the lesioned areas were added to this registration process. Next, the mean FA image was created and thinned to create a mean FA skeleton which represents the centers of all tracts common to the group. Each subject's aligned FA data was then projected onto this skeleton and the resulting data fed into voxel-wise cross-subject statistics. This process was repeated for the MD and RD maps by applying the transformations previously calculated with the FA maps.

2.4. *Deterministic tractography*

In the DT analysis, we included all the WM pathways connecting to the STG/MTG (AF, IFOF, ILF, UF, CC, and tapetum) and inferior and medial frontal gyri [AF, IFOF UF, FAT] (see Fig. 1). Dissections of individual WM tracts were performed using TrackVis (version 0.6.0.1, Build 2015.04.07) and following commonly used published guidelines (see below) for the number and positioning of the regions of interest (ROIs; see Supplementary Fig. 1) in both healthy and clinical populations. In all of the WM tracts included, the individual-level ROIs were first defined in the left and right hemispheres in the 6-months images and then copied to the acute and 3-month images to avoid varying ROI sizes affecting the results. The ROIs placed in the acute and 3-month images were spatially and manually adjusted to achieve as accurate tracking as possible. Exclusion ROIs were used when necessary. All ROIs were initially defined large enough to have at least one empty ROI voxel between the tracked fibers and the edge of the ROI to ensure no relevant fibers were missed (Glasser & Rilling, 2008). All analyses were performed by one person (author A.J.S.) blinded to the patients' music perception profile. In the following paragraphs, the way in which every tract of interest was dissected is covered.

The AF comprises three pathways: (i) a long direct segment connecting the temporal lobe to the frontal lobe, (ii) an anterior indirect segment connecting the frontal lobe and the inferior parietal lobule (IPL), and (iii) a posterior indirect segment connecting the temporal lobe and the IPL (Catani, Jones, & ffytche, 2005). To dissect these three AF segments, we used a three-ROI approach (Catani et al., 2005; Francois et al., 2016; Glasser & Rilling, 2008; Sierpowska et al., 2017; Vaquero, Rodriguez-Fornells, & Reiterer, 2016), where the first ROI was drawn on a coronal plane to capture all the fibers running in the anterior-posterior direction using a DTI FA color map, the second ROI on an axial plane near temporo-parietal junction to capture fibers running to the temporal lobe, and the third ROI on a sagittal plane to capture fibers connecting to the IPL.

The IFOF connects occipital, posterior temporal, and orbitofrontal areas (Catani et al., 2002; Kier et al., 2004; Martino et al., 2010; Sarubbo et al., 2013; Turken & Dronkers, 2011). The IFOF was dissected using two ROIs defined on the coronal plane (Catani & Thiebaut de Schotten, 2008; Francois et al., 2016; Lopez-Barroso et al., 2013): the first ROI was placed between the occipital and temporal lobe and the second ROI to the anterior floor of the external/extreme capsule.

The ILF connects the occipital cortex with the temporal pole (Catani et al., 2002). The ILF was dissected with two ROIs drawn on the coronal plane: the first ROI was placed in the anterior temporal lobe and the second ROI in the WM of the occipital lobe (Catani & Thiebaut de Schotten, 2008; Francois et al., 2016).

The UF connects the temporal pole and anterior MTG with the superior, middle, and inferior frontal gyri (Kier et al., 2004). The UF was dissected with two ROIs in coronal plane: the first ROI was placed in the anterior floor of the external/extreme capsule and the second ROI in the anterior temporal lobe (Catani & Thiebaut de Schotten, 2008; Francois et al., 2016).

The CC connects homologous areas in left and right hemispheres. We dissected the whole CC using a single ROI defined around the CC in a midsagittal slice (Catani & Thiebaut de Schotten, 2008). The CC also connects both temporal lobes with temporal projections known as the tapetum, and to analyze the tapetum separately, ROIs in the temporal projections of CC were created in the axial plane (Huang et al., 2005).

The FAT is a recently discovered WM tract connecting the IFG and pre-SMA and SMA regions (Catani et al., 2013; Sierpowska et al., 2015). The FAT was dissected with two ROIs: the first ROI was placed in axial plane to pre-SMA and SMA and the second ROI in sagittal plane to IFG (Catani et al., 2013; Sierpowska et al., 2015). When needed, each patients' T1 images were used as guidelines to locate the central sulcus and the precentral gyrus and sulcus to define the pre-SMA/SMA area.

In the acute stage, the CC, tapetum, left AF (posterior segment), left UF, and left ILF were successfully traced in all subjects. The tracing was unsuccessful in the left AF (anterior segment, $N = 2$; long segment, $N = 1$), left FAT ($N = 5$), left IFOF ($N = 1$), right AF (anterior segment, $N = 8$; long segment $N = 8$; posterior segment $N = 7$), right FAT ($N = 5$), right IFOF ($N = 4$), right UF ($N = 2$), and right ILF ($N = 1$). Statistical characteristics of the WM tracts are presented in Supplementary Tables 1, 2, and 3.

2.5. *Statistical analysis*

We first compared the differences in TBSS results for NA, RA, and NRA patients using independent samples *t*-test at each time point (Acute, 3 months, 6 months). At each point, we calculated six different contrasts: NRA > NA, NRA > RA, NA > NRA, NA > RA, RA > NRA, RA > NA. In addition, 12 different interactions [Group (NRA > NA, NRA > RA, NA > NRA, NA > RA, RA > NRA, RA > NA) × Time (3 months > Acute, 6 months > Acute) were calculated to evaluate longitudinal changes. Additionally, rhythm and pitch amusia were evaluated using the same preceding contrasts but with pNRA, pRA and pNA, and rNRA, rRA and rNA groups. Unless otherwise

noted, TBSS results are reported with a familywise error rate (FWE) corrected $p < .05$ threshold using threshold-free cluster enhancement and a non-parametric (Smith & Nichols, 2009) permutation test with 5000 permutations (Nichols & Holmes, 2002).

To compare the differences between the previously defined groups in tractography results in amusic, pitch-amusic, and rhythm-amusic subjects, statistical information (tract volume, FA, MD and RD value) of each tract in the three different time points was gathered using a MATLAB toolbox (The MathWorks Inc., Natick, MA, USA, version R2012b), "along-tract statistics" (Colby et al., 2012). Statistical information was then further analyzed with SPSS (IBM Corp. Released 2012. IBM SPSS Statistics for Windows, Version 21.0. Armonk, NY: IBM Corp.). We performed second-level analysis using a mixed between-within repeated-measures analysis of variance [ANOVA; Group (RA/NRA/NA) × Time (Acute, 3 months, 6 months)]. Similarly, pNRA, pRA, and pNA as well as rNRA, rRA, and rNA were compared to evaluate tractography results in pitch and rhythm amusia. Three covariates were used in all analyses and time points: educational years, acute lesion size, and a composite (average) score of acute stage verbal memory performance (derived from a word-list learning and Rivermead Behavioural Memory Test story recall tasks; Särkämö et al., 2008), which were available for all patients. Given that memory deficits are among the most prevalent cognitive impairments after stroke (Nys et al., 2007) and that the MBEA has a clear working memory component, including this variable as a covariate in the analyses controls the potential impact of cognitive deficits on the results. The pNRA and rRNA groups had more right hemisphere damaged (RHD) patients in all of the analyses. According to our previous study (Sihvonen et al., 2016), the acquired amusia stems from RHD and thus it would have been counterintuitive to add lesion laterality as a covariate in the analyses. There was a significant group difference in visual neglect occurrence in the pitch amusia grouping, but importantly the pNRA and pRA groups did not show significant differences (χ^2, $p = .629$). The coincidence of neglect and amusia is expected due their similar lesion locations (Chechlacz, Rotshtein, & Humphreys, 2012), and thus was not included as a covariate in the analyses. Correction for multiple comparisons in *post hoc* analyses was made with the Bonferroni adjustment.

To evaluate which of the significant tractography results were the strongest predictors of MBEA performance, a stepwise linear regression analysis including only the significant tractography results was performed. Additionally, using similar principles, a linear regression analysis using the Information Criteria (AICc) as selection for variable entry and removal was carried out. Based on the regression analysis results, a Pearson correlation between the MBEA performance and the most significant predictor in all three time points was also carried out. Correction for multiple comparisons in the correlations was made with the Bonferroni adjustment (only three correlations were calculated).

To verify that the music intervention did not effect on amusia recovery, we calculated a mixed-model ANOVA with Time (acute/3-month/6-month) and Group (3 intervention arms). No significant Time × Group or between-subjects effects were found in the MBEA average score (Within-subject $p = .825$, Between-subject $p = .483$), the MBEA Scale subtest score (Within-subject $p = .839$, Between-subject $p = .764$), or the MBEA Rhythm subtest score (Within-subject $p = .791$, Between-subject $p = .224$). These results suggest that the music listening intervention did not have any effect on amusia recovery and, therefore, does not impact the results of the present study.

3. Results

3.1. *Tract-based spatial statistics: amusia*

All TBSS results reported here are FWE-corrected with a $p < .05$ threshold. Cross-sectional TBSS analyses of Group (NRA/RA/NA) effects (see Table 3, Fig. 2) consistently showed that the NRA group had significantly lower FA in the right IFOF, AF, UF, internal capsule (IC), and CC than the NA group at the acute, 3-month, and 6-month stages. At the 3-month and 6-month stages, the NRAs additionally showed lower FA in the tapetum as well as greater MD and RD in the right IFOF, AF, UF, CC, and tapetum compared to the NAs. Importantly, although

Table 3 – TBSS results of cross-sectional analyses for persistent amusia, pitch-amusia, and rhythm amusia.

Tract	FA			MD			RD		
	A	3	6	A	3	6	A	3	6
Amusia									
R IFOF	↓	↓	↓/–		↑	↑/+		↑	↑/+
R UF	↓	↓	↓/–		↑	↑/+		↑	↑/+
R AF	↓	↓	↓/–		↑	↑/+		↑	↑/+
R IC	↓	↓	↓						↑
CC	↓	↓	↓					↑	
Tapetum		↓	↓			↑		↑	↑
Pitch-amusia									
R IFOF	↓	↓	↓		↑	↑	↑	↑	↑
R UF	↓	↓	↓		↑	↑		↑	↑
R ILF	↓	↓	↓		↑		↑	↑	↑
R AF	↓	↓	↓		↑	↑	↑	↑	↑
R IC	↓	↓	↓				↑	↑	↑
CC	↓	↓	↓		↑	↑	↑	↑	↑
Tapetum		↓	↓						
Rhythm-amusia									
R IFOF	↓	↓	↓		↑	↑		↑	↑
R UF	↓	↓	↓		↑	↑		↑	↑
R ILF	↓	↓	↓			↑			↑
R AF	↓	↓	↓		↑	↑		↑	↑
R IC	↓	↓	↓						
L AF									↑
CC	↓	↓	↓		↑	↑		↑	↑
Tapetum						↑			↑

Non-recovered amusics versus non-amusics (arrow up or down), and non-recovered amusics versus recovered amusics (+or –). Arrow up or + indicates greater value and arrow down or – a lower value for the contrast in question.
All results are thresholded at a FWE-corrected $p < .05$ threshold.
3 = 3 months stage, 6 = 6 months stage, A = Acute.
AF = Arcuate fasciculus, CC = Corpus callosum, FA = Fractional anisotropy, IC = Internal capsule.
IFOF = Inferior fronto-occipital fasciculus, ILF = Inferior longitudinal fasciculus, L = Left, MD = Mean diffusivity.
R = Right, RD = Radial diffusivity, UF = Uncinate fasciculus.

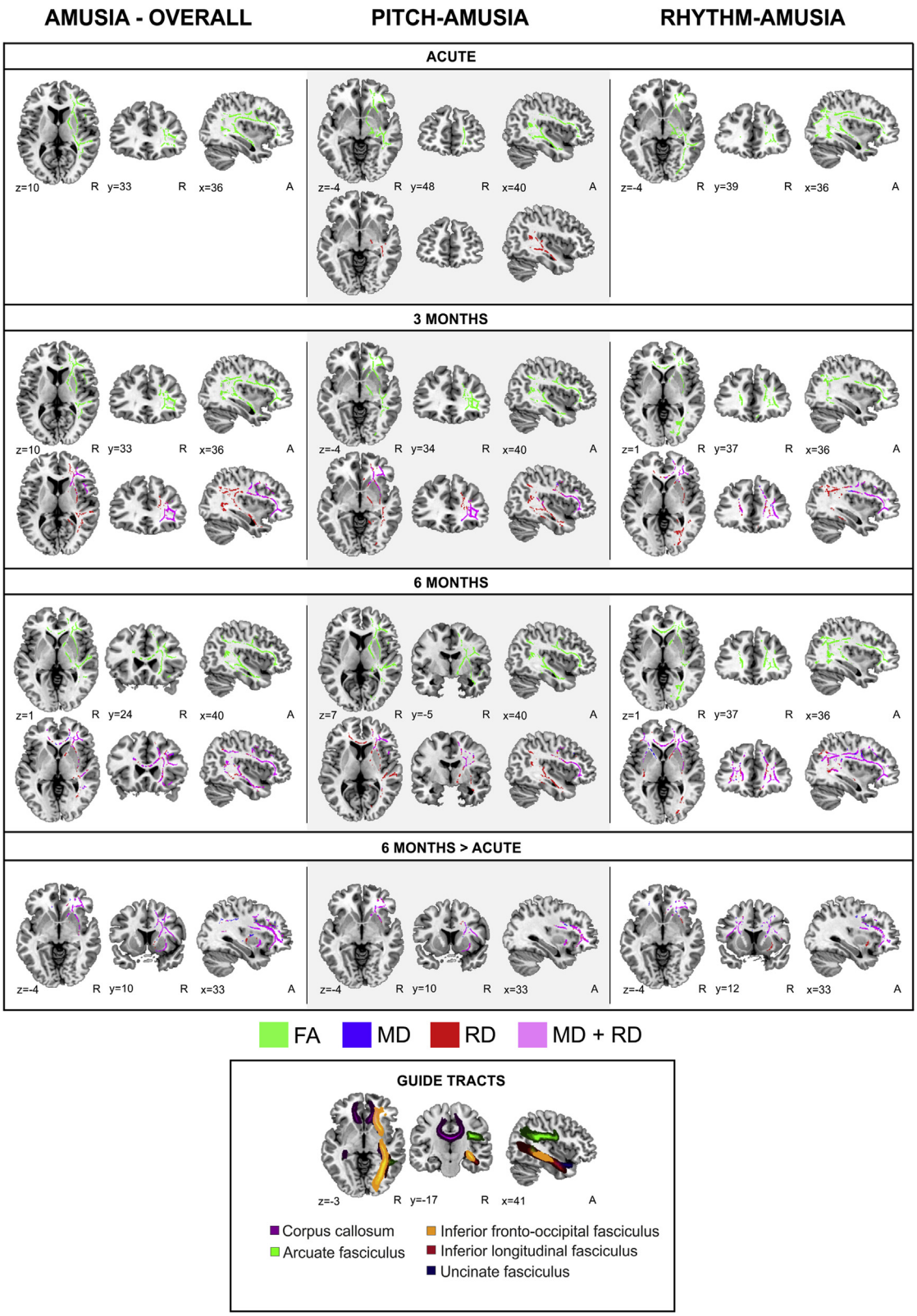

Fig. 2 – TBSS results for persistent acquired amusia. Lower FA and increased MD and RD values are presented for persistent amusia, pitch-amusia, and rhythm-amusia cross-sectionally in all three time points and Group (NRA *vs* NA/pNRA *vs* pNA/rNRA *vs* rNA) × Time (6 months > Acute) interaction. A guide map of appropriate WM tracts is presented at the bottom (http://www.natbrainlab.co.uk/atlas-maps). N = 42. Neurological convention is used with MNI coordinates at the middle each section. All statistical maps are thresholded at a FWE-corrected $p < .05$ threshold. FA = Fractional anisotropy, MD = Mean diffusivity, RD = Radial diffusivity.

Please cite this article in press as: Sihvonen, A. J., et al., Tracting the neural basis of music: Deficient structural connectivity underlying acquired amusia, Cortex (2017), https://doi.org/10.1016/j.cortex.2017.09.028

Table 4a – Significant group and group × time interactions of tractography analyses.

Group effects						Group × time interactions					
Tract	Variable	*df*	F	P	η^2	Tract	Variable	*df*	F	P	η^2
Amusia						**Amusia**					
R IFOF	VOL	2, 36	3.9	.030	.177	Tapetum	MD	4, 72	4.3	.003	.194
	FA	2, 36	4.5	.018	.200		RD	4, 72	3.9	.006	.178
R FAT	VOL	2, 36	4.6	.017	.202						
R AF Long seg.	VOL	2, 36	3.5	.041	.163						
L AF Post. Seg.	VOL	2, 36	4.1	.025	.184						
Pitch-amusia						**Pitch-amusia**					
R IFOF	VOL	2, 36	3.6	.038	.167	R AF Ant. seg.	MD	4, 72	4.5	.003	.201
	FA	2, 36	4.3	.022	.191		RD	4, 72	4.4	.003	.198
						R UF	MD	4, 72	4.0	.005	.183
							RD	4, 72	4.0	.005	.182
						Tapetum	MD	4, 72	3.3	.015	.156
							RD	4, 72	3.3	.015	.155
Rhythm-amusia						**Rhythm-amusia**					
R IFOF	VOL	2, 36	4.5	.018	.201	L UF	RD	4, 72	2.7	.035	.132
R UF	VOL	2, 36	3.3	.048	.155						
CC	FA	2, 36	4.1	.025	.185						
	MD	2, 36	4.9	.013	.214						
	RD	2, 36	4.2	.023	.188						

Statistical information presented: df = degrees of freedom, F = f value, P = *p*-value, η^2 = partial eta squared.
AF = Arcuate fasciculus, CC = Corpus callosum, FA = Fractional anisotropy, FAT = Frontal Aslant Tract, IFOF = Inferior fronto-occipital fasciculus.
L = Left, MD = Mean diffusivity, R = Right, RD = Radial diffusivity, UF = Uncinate fasciculus, VOL = Volume.

the NRAs and RAs did not differ at the acute and 3-month stages, at the 6-month stage the NRAs did show lower FA and greater MD and RD in the right IFOF, AF, and UF. No other contrasts were significant at the acute, 3-month, and 6-month stages.

Longitudinal TBSS analyses of Time × Group interactions (acute to 3-month/acute to 6-month; see Fig. 2) showed that in the NRAs compared to the NAs the MD of the right IFOF, AF, UF, IC, CC, and tapetum increased more from the acute to 3-month and 6-months stages and also the RD of the right IFOF, AF, UF, and IC increased more from the acute to 3-month stage. The NRAs also showed a greater RD increase in the right IFOF, AF, UF, IC, CC, and tapetum than the NAs from the acute to 6-month stage. In addition, there was a greater MD increase in the RAs compared to the NAs in the left IFOF and CC from the acute to 3-month and 6-month stages as well as in the left AF and UF and in the CC from the acute to the 6-month stage. No other significant interactions were observed.

3.2. *Tract-based spatial statistics: pitch-amusia and rhythm-amusia*

We performed the TBSS analyses also separately for pitch-amusia (pNRA/pRA/pNA) and rhythm-amusia (rNRA/rRA/rNA; see Table 3, Fig. 2). Results reported here are all FWE-corrected with a $p < .05$ threshold. Cross-sectionally, these analyses yielded essentially the same pattern of results as presented above: both pNRAs and rNRAs showed lower FA and greater MD and/or RD in the right IFOF, AF, UF, CC, and tapetum than the pNAs and rNAs, respectively, at all stages studied. In addition, the same FA and MD/RD effects were seen also in the right ILF for both pNRAs and rNRAs compared to the pNAs and rNAs, respectively. Furthermore, compared to the pNAs, the pNRAs showed decreased FA and increased RD in the right IC at all the three time points.

Separate longitudinal TBSS interactions likewise showed that the MD and RD of the right IFOF, AF, and UF increased more in the pNRAs than in pNAs from acute to 3-month and 6-month stages and also more in the rNRAs than in the rNAs from acute to 6-month stage. Interestingly, for the rNRAs there was an additional increase from acute to 6-month stage also in the RD of the left AF compared to the rNAs. In addition, the pRAs showed increased MD in the right AF, IFOF, and in the CC compared to the pNA group from the acute to 3-month stage but not to 6-month stage.

3.3. *Deterministic tractography: amusia*

The results of the DT are presented in Table 4a and Fig. 3. A mixed-model ANOVA with Time (acute/3-month/6-month) and Group (NRA/RA/NA) revealed significant between-subjects effects in the volume of the right IFOF [$F(2,36) = 3.881$, $p = .030$], AF long segment [$F(2,36) = 3.500$, $p = .041$], and FAT [$F(2,36) = 4.553$, $p = .017$] and the left AF posterior segment [$F(2,36) = 4.072$, $p = .025$] as well as in the FA of the right IFOF [$F(2,36) = 4.486$, $p = .018$]. Post hoc testing showed that compared to the NRAs both the NAs and the RAs had significantly greater right IFOF volume ($p = .002$ and $p = .036$, respectively) and FA ($p = .002$; $p = .027$) as well as greater right AF long segment volume ($p = .019$; $p = .016$). The NRAs also showed lower right FAT volume ($p = .049$) than the NAs. In contrast, the RAs had lower left AF posterior segment volume than the NAs ($p = .017$).

In addition, there were significant Time × Group interactions in the MD [$F(4,72) = 4.322$, $p = .003$] and RD

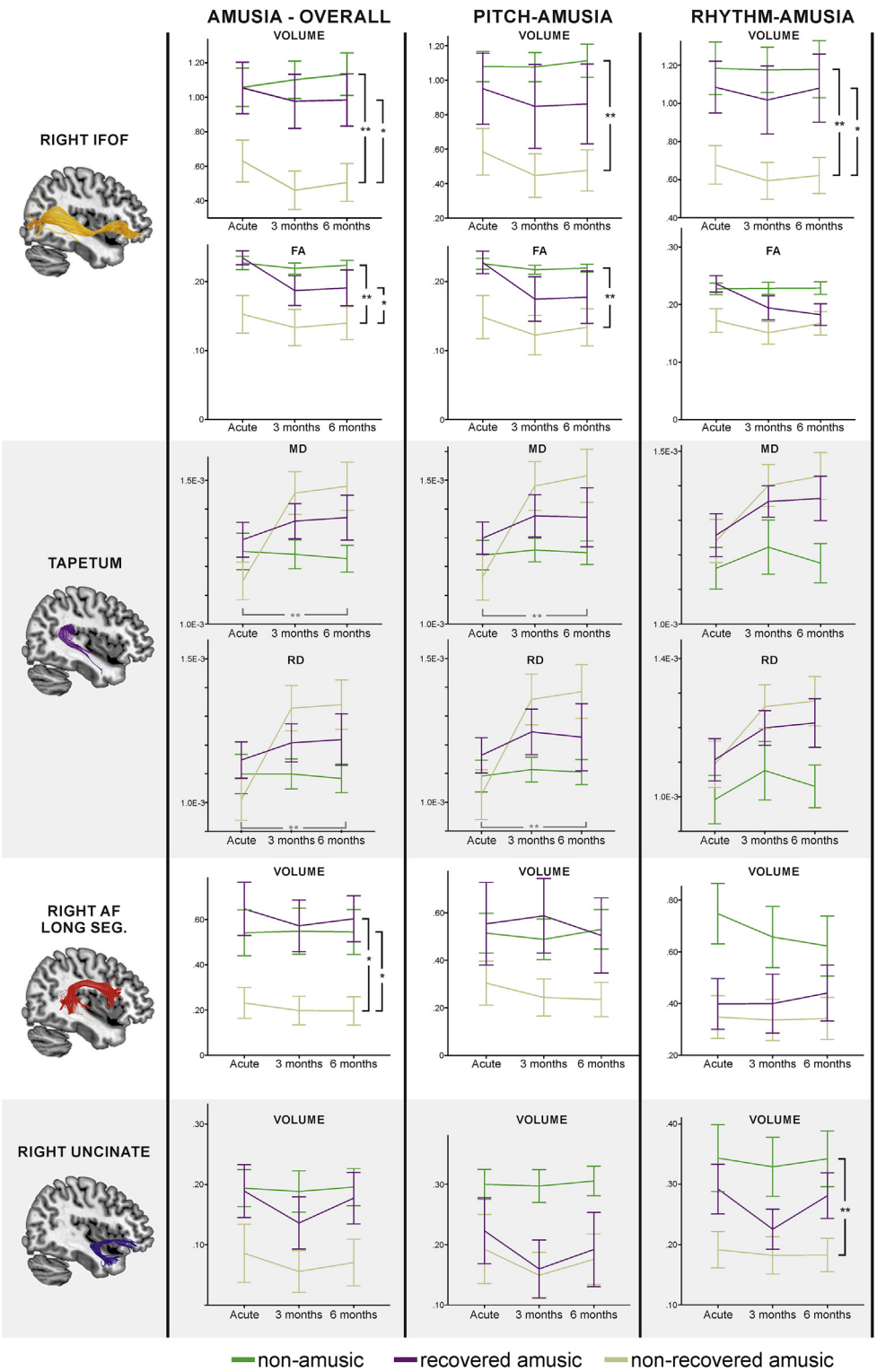

Fig. 3 – Main tractography results. Group × Time (Acute, 3 months, 6 months) repeated measured results. Significant Group effect (black bar), significant Group × Time interaction (gray bar). Error-bar = standard error of the mean. AF = Arcuate fasciculus, FA = Fractional anisotropy, IFOF = Inferior fronto-occipital fasciculus, MD = Mean diffusivity, RD = Radial diffusivity, VOL = Volume. *$p < .05$ **$p < .01$.

[F(4,72) = 3.909, $p = .006$] of the tapetum. From acute to the 6-month stage, the NRAs showed greater increase in the tapetum MD ($p = .001$) and RD ($p = .002$) than the NAs. No other significant interactions were observed.

3.4. *Deterministic tractography: pitch-amusia*

As with the TBSS, also the DT analyses were performed separately for pitch-amusia (see Table 4a and Fig. 3) where

significant between-subject (Group) effects were observed in the volume [F(2,36) = 3.597, p = .038] and FA [F(2,36) = 4.263, p = .022] of the right IFOF with post hoc tests revealing lower volume and FA in the pNRAs than pNAs (p = .001; p < .001). Significant Time × Group interactions were found in the MD [F(4,72) = 3.331, p = .015] and RD [F(4,72) = 3.308, p = .015] of the tapetum and in the MD [F(4,72) = 4.530, p = .003] and RD [F(4,72) = 4.446, p = .003] of the right AF anterior segment as well as in the MD [F(4,72) = 4.020, p = .005] and RD [F(4,72) = 4.013, p = .005] of the right UF. Post hoc tests indicated a greater increase from acute to 6-month in the pNRAs than pNAs for the tapetum MD (p = .002) and RD (p = .002) and for the right AF anterior segment MD (p = .001) and RD (p = .001). In addition, the pNRAs showed a greater increase in the right UF MD (p = .030) and RD (p = .030) than the pNAs and the pRAs showed a greater decrease in the right AF anterior segment MD and RD compared to the pNAs (p = .004 in both). No other significant interactions were observed.

3.5. *Deterministic tractography: rhythm-amusia*

In rhythm-amusia, significant between-subject (Group) effects were found in the volume [F(2,36) = 4.536, p = .018] of the right IFOF (see Table 4a and Fig. 3). Post hoc tests revealed that the rNRAs had lower volume (p = .008) than the rNAs. The right IFOF volume was also lower in the rNRAs than rRAs (p = .040). Rhythm-amusia also showed additional between-subject effects in the right UF volume [F(2,36) = 3.299, p = .048] with post hoc tests indicating lower volume in the rNRAs than in the rNAs (p = .009). Additional group effects were observed in the FA [F(2,36) = 4.900, p = .013], MD [F(2,36) = 4.181, p = .023], and RD [F(2,36) = 4.327, p = .021] of the CC. Post hoc tests showed, that the rNRAs had greater CC MD (p = .026) and RD (p = .025) than the rNAs. The rRAs had lower CC FA than the rNAs (p = .010).

Interestingly, the longitudinal tractography results revealed a somewhat different pattern of effects for the rhythm-amusia than the pitch-amusia. In rhythm-amusia, significant Time × Group interaction was found in the RD of the left UF [F(4,72) = 2.740, p = .035]. Post hoc tests revealed that the left UF RD increased more in the rNAs than rNRAs from acute to 6-month stage (p = .014). No other significant interactions were observed.

3.6. *Deterministic tractography: regression analysis*

Given the large number of WM pathways and their parameters (volume, FA, MD, RD) implicated in amusia in the DT analyses above, we performed stepwise linear regression analyses to further determine which of these were the strongest predictors of music perception performance. Three different models (for MBEA overall score, Scale subtest score, and Rhythm subtest score) were formed for each time point (acute/3-month/6-month) where all the tracts and their parameters that showed significant effects were entered as independent variables. For MBEA overall score, seven variables were entered: volumes of the right IFOF, AF (long segment), FAT and the left AF (posterior segment) as well as FA of the right IFOF and MD and RD of the tapetum. For MBEA Scale subtest score, eight variables were entered: volume and FA of the right IFOF as well as MD and RD of the right AF (anterior segment), UF, and tapetum. For MBEA Rhythm subtest, five variables were entered: volumes of the right IFOF and UF, FAs of the right IFOF and CC as well as the RD of the left UF.

As shown in Table 4b, the volume of the right IFOF was the most significant predictor of the MBEA overall, Scale, and Rhythm scores across all time points. The left AF posterior segment volume and the tapetum MD/RD emerged as additional predictors of the MBEA overall score at the acute and 3-month/6-month stages, respectively. Across all time points, the Rhythm scores were predicted only by the right IFOF volume, while the Scale scores were predicted also by the tapetum RD and the right UF MD at the 6-month stage.

Using the same previous models, we also carried out a forward stepwise regression analysis using the Information Criterion (AICc) as selection for variable entry and removal. This analysis yielded exactly same results as the linear regression analysis presented above (Table 4b).

We then carried out three Pearson correlations using the volume of the right IFOF (since it was the best predictor) and MBEA total, scale, and rhythm scores at 6-month stage. Correction for multiple comparisons was adjusted with Bonferroni correction (.05/3 = .0167). As presented in Fig. 4, the volume of the right IFOF was significantly correlated with the MBEA overall performance [r(42) = .595, p < .001] as well as the individual subtests [Scale r(42) = .580, p < .001 and Rhythm r(42) = .498, p = .001] at 6 months post-stroke stage.

4. Discussion

The aim of the present study was to systematically and comprehensively explore the role of different WM pathways in acquired amusia using two complementary DTI analysis methods (TBSS and DT). These methods were chosen to (i) provide different level of evidence (voxel *vs* tract level) on WM tract changes in amusia and (ii) to complement each other and overcome the methodological limitations involved in either of the methods used alone. TBSS involves automatic alignment of each patient to the template which may be suboptimal and therefore cause biased results for patients with damaged brain (Bach et al., 2014). However, the tractography dissections were done in native space which expunges the problem of automatic alignment in TBSS. Most importantly, the results from these two methods converge. Our key results were that (i) persistent amusia was associated with damage to many WM pathways primarily in the right hemisphere, (ii) the pattern of WM damage was mostly similar for pitch-amusia and rhythm-amusia, although there were some differences in certain interhemispheric tracts as well as in the laterality of specific intrahemispheric tracts, and (iii) the time course of the changes in WM indices was partly different across the tracts, although the extent of the initial damage had a strong impact on the recovery of amusia. Overall, these findings are closely in line with our previous results indicating that acquired amusia is associated with a lesion pattern comprising the right STG, HG, insula, and striatum, with further reduced GMV in the right STG/MTG in NRA patients (Sihvonen et al., 2016).

Table 4b – Regression analysis of the tractography results.

Model	Variable	AICc	Beta	T	F(df)	R^2	R^2 change
Acute							
MBEA % – overall							
1					F(1,40) = 14.162	.261	.261
	R IFOF volume	215.327	.511	3.763**			
2					F(1,39) = 4.163	.333	.071
	R IFOF volume	213.391	.484	3.684**			
	L AF post. volume		.268	2.040*			
MBEA % – Scale subtest							
1					F(1,40) = 11.259	.220	.220
	R IFOF volume	240.185	.469	3.355**			
MBEA % – Rhythm subtest							
1					F(1,40) = 9.186	.187	.187
	R IFOF volume	214.879	.432	3.031**			
3 months							
MBEA % – overall							
1					F(1,40) = 24.905	.384	.384
	R IFOF volume	206.377	.619	4.990**			
2					F(1,39) = 15.677	.446	.062
	R IFOF volume	204.251	.535	4.248**			
	Tapetum RD		−.263	−2.088*			
MBEA % – Scale subtest							
1					F(1,40) = 17.396	.303	.303
	R IFOF volume	228.594	.551	4.171**			
MBEA % – Rhythm subtest							
1					F(1,40) = 24.593	.381	.381
	R IFOF volume	204.520	.617	4.959**			
6 months							
MBEA % – overall							
1					F(1,40) = 21.874	.354	.354
	R IFOF volume	211.189	.595	4.677**			
2					F(1,39) = 14.640	.429	.075
	R IFOF volume	208.312	.479	3.642**			
	Tapetum MD		−.298	−2.267*			
MBEA % – Scale subtest							
1					F(1,40) = 20.268	.336	.336
	R IFOF volume	228.035	.580	4.502**			
2					F(1,39) = 14.791	.431	.095
	R IFOF volume	223.868	.453	3.464**			
	Tapetum RD		−.334	−2.553*			
3					F(1,38) = 12.777	.502	.071
	R IFOF volume	220.729	.521	4.095**			
	Tapetum RD		−.397	−3.128**			
	R UF MD		−.288	−2.325*			
MBEA % – Rhythm subtest							
1					F(1,40) = 13.189	.248	.248
	R IFOF volume	215.786	.498	3.632**			

Statistical information presented: AICc = Akaike information criterion (corrected), Beta = standardized regression coefficient, T = t value, F(df) = F value (degrees of freedom), R2 = R Square, R2 change = R Square change. AF = Arcuate fasciculus, IFOF = Inferior fronto-occipital fasciculus, L = Left, MD = Mean diffusivity, MBEA = Montreal Battery of Evaluation of Amusia, R = Right, RD = Radial diffusivity, UF = Uncinate fasciculus. $^{*}p < .05$; $^{**}p < .005$.

4.1. *Intrahemispheric tracts*

Previous neuroimaging studies suggest that congenital amusia stems from deficits in frontotemporal connectivity (Albouy et al., 2013; Leveque et al., 2016) or dysfunction of prefrontal areas, especially the IFG (Albouy et al., 2013; Hyde et al., 2006, 2007; Omigie, Müllensiefen, & Stewart, 2012). The AF has been considered as the primary pathway involved in amusia (Loui et al., 2009), but as conflicting evidence exits (Chen et al., 2015) and the implication of other frontotemporal tracts remain unexplored in amusia, this statement needs to be confirmed.

Our novel finding was that persistent acquired amusia was linked to clear damage of the right IFOF and ILF, and that the right IFOF was in fact the strongest predictor of MBEA performance (see Table 4b and Fig. 4). These ventral tracts, originating from posterior occipital and temporal regions, run laterally and inferiorly to the anterior temporal lobe (ILF) and through posterior temporal lobe and then medially to the orbitofrontal and inferior frontal areas (IFOF). Although their exact function remains unknown, they may be involved in language processing in the left hemisphere, and in particular in the process of mapping sound to semantic

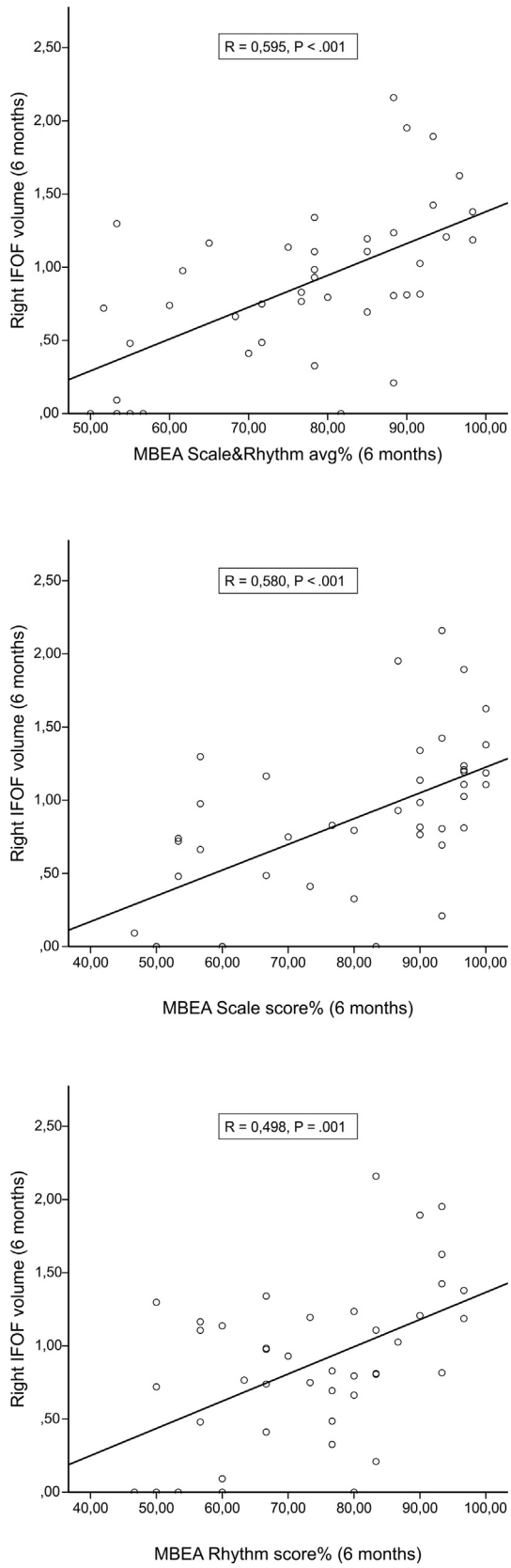

Fig. 4 – Scatter plots indicating the relationships between the right IFOF volume and the MBEA performance at 6-month post-stroke stage. Two-tailed tests were used to determine the significance. IFOF = Inferior fronto-occipital fasciculus, MBEA = Montreal Battery of Evaluation of Amusia, P = Probability value, R = Pearson correlation.

meaning (Dick & Tremblay, 2012; Saur et al., 2008). In the auditory-music domain, the IFOF and ILF have thus far been linked to absolute pitch (Dohn et al., 2015), musical synesthesia (Zamm et al., 2013), and hearing loss (Husain et al., 2011). From ontogenetic and phylogenetic standpoints, the contribution of the right IFOF to music cognition is particularly interesting since in humans it is known to be present already at birth (Perani et al., 2011), but is clearly less developed in monkeys (Thiebaut de Schotten, Dell'Acqua, Valabregue, & Catani, 2012). Overall, our findings converge with the proposal of recent dual-stream studies on music-syntactic (Musso et al., 2015) and prosodic (Sammler et al., 2015) processing in the healthy brain showing that this takes place along both ventral (IFOF, ILF) and dorsal (AF) routes, which together transform complex acoustic feature combinations into abstract representations and analyze and integrate sensorimotor information with these representations (Rauschecker & Scott, 2009). Our results suggest that normal music perception relies on this dual route especially in the right hemisphere.

In addition to the right IFOF, persistent amusics showed increased axonal damage (higher MD/RD) in the right AF and ILF. The differences in FA and volume were primarily present at the acute post-stroke stage whereas the MD/RD effects emerged in the follow-up, indicating that further degeneration of these pathways is linked to persistent amusia (Ivanova et al., 2016; Yu et al., 2009). Conversely, in the regression analysis of DT data, the volume of the left AF posterior segment was linked to higher MBEA overall scores at the acute stage. Previous DTI studies provide corroborating evidence for the role of the AF/SLF in music processing. The right AF is implicated in congenital amusia (Loui et al., 2009), the left AF in musicians' absolute pitch (Loui, Li, Hohmann, & Schlaug, 2011; Oechslin et al., 2010), and bilateral/right AF more generally in musical training (Bengtsson et al., 2005; Halwani et al., 2011).

We observed also amusia-related changes in the UF and in the FAT. Although the exact functions of these tracts are still incompletely understood, there is evidence for the general role of the left and right UF in social-emotional processing and for the left UF in episodic memory and language semantic processing (Dick & Tremblay, 2012; Von Der Heide, Skipper, Klobusicky, & Olson, 2013). The left and right FAT have been associated with working memory (Rizio & Diaz, 2016) and the left FAT with speech fluency (Sierpowska et al., 2015). In the auditory domain, the UF may be involved in auditory working memory (Diehl et al., 2008), recognizing and attaching emotional significance to sounds (Schmahmann & Pandya, 2006), and absolute pitch (Dohn et al., 2015). Moreover, the SMA and pre-SMA are known to be key nodes in the perception of musical rhythm or beat (Chen et al., 2008; Zatorre, Chen, & Penhune, 2007), which may partly explain why amusia was associated with lower volume of the FAT connecting these regions with the IFG. Based on our results, we suggest tentatively that UF and FAT may contribute especially to the attention- and working memory-based online comparison of sequential sounds required for music perception, with additional involvement of the UF in the emotional processing of music.

Please cite this article in press as: Sihvonen, A. J., et al., Tracting the neural basis of music: Deficient structural connectivity underlying acquired amusia, Cortex (2017), https://doi.org/10.1016/j.cortex.2017.09.028

4.2. Interhemispheric tracts

Our analysis of the interhemispheric tracts suggests that persistent amusia is linked not only to damage in right intrahemispheric tracts, but also to reduced structural connectivity between the right and left superior temporal regions. Coupled with the fact that the amusics had more extensive lesions and cortical atrophy in the right STG/MTG than NAs (Sihvonen et al., 2016), these findings are consistent with recent studies showing that inhibiting the right AC with transcranial magnetic stimulation reduces connectivity between the auditory cortices (Andoh, Matsushita, & Zatorre, 2015) and that the strength of interhemispheric callosal auditory pathways is related to better performance in an auditory speech perception task (Westerhausen, Gruner, Specht, & Hugdahl, 2009). Musicians, compared to non-musicians, have been shown to have larger volume/FA in the anterior (Bengtsson et al., 2005; Schlaug et al., 1995; Schmithorst & Wilke, 2002) and posterior (Bengtsson et al., 2005; Burunat et al., 2015) CC, and also exhibit more hemispherically symmetric activity patterns when listening to music (Burunat et al., 2015). In contrast, reduced lateral connectivity between the left and right AC has been reported also in congenital amusics during the memory-based processing of tone changes measured by magnetoencephalography (Albouy, Mattout, Sanchez, Tillmann, & Caclin, 2015).

4.3. Differences in pitch-amusia and rhythm-amusia

Separate analyses for pitch-amusia and rhythm-amusia yielded a largely overlapping pattern of effects, although there were some notable differences, especially in the DT results. A longitudinal MD/RD increase in the right anterior AF, UF, and tapetum was observed in the pNRAs but not in the rNRAs. This is well in line with the previously observed GMV decrease in right posterior temporal areas in the pNRAs (Sihvonen et al., 2016). In the regression analysis, the MD/RD of the tapetum and right UF also emerged as significant predictors of MBEA Scale (but not Rhythm) performance at the 6-month post-stroke stage. Interestingly, compared to the pNAs the pRAs in turn showed a longitudinal MD/RD decrease in the right anterior AF, suggesting that the recovery of pitch-amusia may be linked to better preservation of this pathway connecting the IFG with IPL. This may be related to tonal working memory since the right IPL has been linked specifically to the maintenance of tonal pitch structure in working memory during pitch discrimination (Royal et al., 2016). Overall, these results converge with previous neuroimaging studies (Hyde, Peretz, & Zatorre, 2008; Patterson, Uppenkamp, Johnsrude, & Griffiths, 2002) and lesion studies (Ayotte et al., 2000; Liegeois-Chauvel, Peretz, Babai, Laguitton, & Chauvel, 1998) showing that right superior temporal areas are crucial for pitch and melodic processing. Our results further suggest that also the intra- and interhemispheric connectivity of superior temporal areas as well as right frontal pathways have an important role in pitch-amusia.

Contrary to pitch-amusia, rhythm-amusia was linked to greater increase in RD in the left AF indicating axonal damage. In DT, we also observed lower volume in the right UF as well as higher MD/RD in the CC in the rhythm-amusics but not in the pitch-amusics. The rNRAs also showed lower volume in the right IFOF than rRAs, and right IFOF volume also came out as the only significant predictor of MBEA Rhythm performance in the regression analyses across all three time points. Coupled with our previous findings of grey matter atrophy in right anterior temporal areas and WM atrophy in right inferior temporal areas in the rNRA patients (Sihvonen et al., 2016), these results suggest that persistent rhythm-amusia is associated with more extensive and bilateral damage and degeneration of frontal and frontotemporal pathways than pitch-amusia. This finding is supported by the lack of any clear lateralization effects for temporal processing of music in healthy subjects (Alluri et al., 2012; Samson, Zeffiro, Toussaint, & Belin, 2011), and lesion studies (Ayotte et al., 2000; Liegeois-Chauvel et al., 1998; Rosslau et al., 2015; Schuppert et al., 2000).

4.4. Network for music perception

Functional neuroimaging studies with healthy subjects have implicated bilateral temporal, frontal, parietal, and subcortical brain activations associated with music perception (Alluri et al., 2012; Brattico et al., 2011; Schmithorst, 2005). In general, spatially distributed brain regions subserving a cognitive function are connected via WM pathways to form a neural network maximizing the processing, storage, and manipulation of information (Ross, 2010). Disruption of the network and its WM connections can lead to a disconnection syndrome and a cognitive-behavioral deficit (Catani & Mesulam, 2008; Thiebaut de Schotten et al., 2008). Based on our current results, and in contrast with the bilateral large-scale music network observed in healthy subjects, the critical connections for music perception seem to be located in the right hemisphere, as the disruption of these connections, especially the right IFOF, leads to music perception deficits. The disparity between the lesion data on amusia (right hemisphere) and the functional neuroimaging data on healthy music processing (bilateral) could arise from complexity of the stimuli. In language domain, the lateralization of prosodic emotion processing in the brain is dependent on the verbal complexity: As the complexity increases, the observed brain activity shifts from being dominantly right lateralized to being bilateral (Mitchell & Ross, 2008). Similarly, as music contains complex acoustic components as well as a language component, it is reasonable to expect bilateral wide-spread brain activations whilst listening to music. The effect of the observed disconnection on the whole music network and bilateral activations can only be speculated as functional neuroimaging studies utilizing naturalistic music listening in either congenital or acquired amusia have not been published. Similarly, studies on the functional processing of natural music and speech in amusia would help to shed light on the convergence of the large-scale music and language networks. In addition, as our current patient sample impeded us from carrying out analyses based on lesion laterality, future studies investigating music processing deficits specifically in the left hemisphere damaged patients would be of great interest.

Please cite this article in press as: Sihvonen, A. J., et al., Tracting the neural basis of music: Deficient structural connectivity underlying acquired amusia, Cortex (2017), https://doi.org/10.1016/j.cortex.2017.09.028

Although the core networks processing music and language appear to be somewhat separate, there are some perceptual domains where these two networks converge. One of these interesting convergence points is affective prosody perception, the ability to perceive emotions conveyed through speech, which relies on multiple acoustic ques (e.g., pitch, intonation contours). Neuroimaging studies in healthy subjects suggest that, similar to music, affective prosody perception involves a network of right frontotemporal and bilateral frontal regions and pathways (Frühholz, Gschwind, & Grandjean, 2015; Wildgruber, Ackermann, Kreifelts, & Ethofer, 2006). Interestingly, congenital amusics have been found to have subtle deficits in perceiving affective prosody (Lima et al., 2016; Thompson, Marin, & Stewart, 2012). Also in stroke patients, affective aprosodia has been linked to right hemisphere damage (Jafari, Esmaili, Delbari, Mehrpour, & Mohajerani, 2017; Ross, 2010; Ross & Monnot, 2008), but the precise neural relationship between amusia and aprosodia has never been systematically mapped; this would be an interesting and fruitful topic for future research.

5. Conclusions

Our longitudinal results suggest that persistent acquired amusia after stroke is associated with structural damage and later degeneration in many key frontotemporal, frontal, and interhemispheric pathways. Compared to the existing scanty evidence of tract deficiencies in amusia arising from studies on congenital amusia, this pattern of deficient connectivity is considerably more extensive. We have identified several tracts, including the IFOF, ILF, UF, FAT, CC, and tapetum, which have never before been linked to amusia. Moreover, both persistent pitch-amusia and rhythm-amusia were associated with impaired right frontotemporal (AF long segment, IFOF, and ILF) and frontal (UF) connectivity, but pitch-amusia showed additional deficits in right frontoparietal connectivity (anterior AF) and interhemispheric temporal connectivity (tapetum) whereas rhythm-amusia showed additional deficits in left frontal connectivity. Obtaining largely converging results by using two imaging methodologies, which are very different in spatial resolution (voxel-level microstructure, whole-brain macrostructure), increases the robustness of our conclusion; this is important given that individual tracking algorithms have their limitations (e.g., in yielding false positives/negatives; Campbell & Pike, 2014; Chen et al., 2015). By studying amusic stroke patients, we provide significant new evidence to extend the current understanding of the crucial brain networks participating in music processing in general and in pitch versus rhythm processing in particular. In addition to the neuroscience perspective of music processing, our findings are relevant in designing future music-related intervention studies on rehabilitation and in interpreting their outcome.

In future, further research on the roles of the musical ventral and dorsal pathways in amusia and music perception in general are needed. Moreover, the relationship between acquired aprosodia and amusia would be an interesting target of investigation. This would provide information on pathways mediating pitch and contour processing in the brain in general and not only in the musical or language domain.

Funding

This work was supported by Academy of Finland program (grants no. 1257077, 1277693), Tyks Research Funding (grant no. 13944), Finnish Brain Research and Rehabilitation Foundation, Finnish Brain Foundation, Ella and Georg Ehrnrooth Foundation, Signe and Ane Gyllenberg Foundation, Maire Taponen Foundation, Finnish Cultural Foundation, National Doctoral Programme of Psychology, Jenny and Antti Wihuri Foundation, the Formación de Profesorado Universitario program (AP2010-4170) and Generalitat de Catalunya (2014 SGR1413).

Acknowledgements

We express our gratitude to the staff of the Tyks Department of Clinical Neurosciences, and rehabilitation hospitals in the Hospital District of Southwest Finland for their collaboration. We thank professor Mari Tervaniemi, M.Sc. Joanna Sierpowska, M.A. Jari Lipsanen, and radiographers Ulla Anttalainen (†), Riku Luoto and Tuija Vahtera. We also thank the patients and their families for their participation.

Supplementary data

Supplementary data related to this article can be found at https://doi.org/10.1016/j.cortex.2017.09.028.

REFERENCES

Abdul-Kareem, I. A., Stancak, A., Parkes, L. M., Al-Ameen, M., Alghamdi, J., Aldhafeeri, F. M., et al. (2011). Plasticity of the superior and middle cerebellar peduncles in musicians revealed by quantitative analysis of volume and number of streamlines based on diffusion tensor tractography. *The Cerebellum, 10*(3), 611–623.

Albouy, P., Mattout, J., Bouet, R., Maby, E., Sanchez, G., Aguera, P. E., et al. (2013). Impaired pitch perception and memory in congenital amusia: The deficit starts in the auditory cortex. *Brain, 136*(Pt 5), 1639–1661.

Albouy, P., Mattout, J., Sanchez, G., Tillmann, B., & Caclin, A. (2015). Altered retrieval of melodic information in congenital amusia: Insights from dynamic causal modeling of MEG data. *Frontiers in Human Neuroscience, 9*, 20.

Alexander, A. L., Hurley, S. A., Samsonov, A. A., Adluru, N., Hosseinbor, A. P., Mossahebi, P., et al. (2011). Characterization of cerebral white matter properties using quantitative magnetic resonance imaging stains. *Brain Connectivity, 1*(6), 423–446.

Alluri, V., Toiviainen, P., Jääskeläinen, I. P., Glerean, E., Sams, M., & Brattico, E. (2012). Large-scale brain networks emerge from dynamic processing of musical timbre, key and rhythm. *NeuroImage, 59*(4), 3677–3689.

Andersson, J. L. R., Jenkison, M., & Smith, S. (2007a). *Non-linear optimisation. FMRIB technical report TR07JA1*.

Andersson, J. L. R., Jenkison, M., & Smith, S. (2007b). *Non-linear registration aka Spatial normalisation. FMRIB technical report TR07JA2*.

Andoh, J., Matsushita, R., & Zatorre, R. J. (2015). Asymmetric interhemispheric transfer in the auditory network: Evidence

from TMS, resting-state fMRI, and diffusion imaging. *The Journal of Neuroscience, 35*(43), 14602–14611.
Ayotte, J., Peretz, I., Rousseau, I., Bard, C., & Bojanowski, M. (2000). Patterns of music agnosia associated with middle cerebral artery infarcts. *Brain, 123*(9), 1926–1938.
Bach, M., Laun, F. B., Leemans, A., Tax, C. M., Biessels, G. J., Stieltjes, B., et al. (2014). Methodological considerations on tract-based spatial statistics (TBSS). *NeuroImage, 100*, 358–369.
Basser, P. J., Pajevic, S., Pierpaoli, C., Duda, J., & Aldroubi, A. (2000). In vivo fiber tractography using DT-MRI data. *Magnetic Resonance in Medicine, 44*(4), 625–632.
Bengtsson, S. L., Nagy, Z., Skare, S., Forsman, L., Forssberg, H., & Ullen, F. (2005). Extensive piano practicing has regionally specific effects on white matter development. *Nature Neuroscience, 8*(9), 1148–1150.
Brattico, E., Alluri, V., Bogert, B., Jacobsen, T., Vartiainen, N., Nieminen, S., et al. (2011). Functional MRI study of happy and sad emotions in music with and without lyrics. *Frontiers in Psychology, 2*, 308.
Burunat, I., Brattico, E., Puoliväli, T., Ristaniemi, T., Sams, M., & Toiviainen, P. (2015). Action in perception: Prominent visuo-motor functional symmetry in musicians during music listening. *PLoS One, 10*(9), e0138238.
Campbell, J. S., & Pike, G. B. (2014). Potential and limitations of diffusion MRI tractography for the study of language. *Brain and Language, 131*, 65–73.
Catani, M., Howard, R. J., Pajevic, S., & Jones, D. K. (2002). Virtual in vivo interactive dissection of white matter fasciculi in the human brain. *NeuroImage, 17*(1), 77–94.
Catani, M., Jones, D. K., & ffytche, D. H. (2005). Perisylvian language networks of the human brain. *Annals of Neurology, 57*(1), 8–16.
Catani, M., & Mesulam, M. (2008). The arcuate fasciculus and the disconnection theme in language and aphasia: History and current state. *Cortex, 44*(8), 953–961.
Catani, M., Mesulam, M. M., Jakobsen, E., Malik, F., Martersteck, A., Wieneke, C., et al. (2013). A novel frontal pathway underlies verbal fluency in primary progressive aphasia. *Brain, 136*(Pt 8), 2619–2628.
Catani, M., & Thiebaut de Schotten, M. (2008). A diffusion tensor imaging tractography atlas for virtual in vivo dissections. *Cortex, 44*(8), 1105–1132.
Chechlacz, M., Rotshtein, P., & Humphreys, G. W. (2012). Neuroanatomical dissections of unilateral visual neglect symptoms: ALE meta-analysis of lesion-symptom mapping. *Frontiers in Human Neuroscience, 6*(230).
Chen, J. L., Kumar, S., Williamson, V. J., Scholz, J., Griffiths, T. D., & Stewart, L. (2015). Detection of the arcuate fasciculus in congenital amusia depends on the tractography algorithm. *Frontiers in Psychology, 6*, 9.
Chen, J. L., Penhune, V. B., & Zatorre, R. J. (2008). Listening to musical rhythms recruits motor regions of the brain. *Cerebral Cortex, 18*(12), 2844–2854.
Colby, J. B., Soderberg, L., Lebel, C., Dinov, I. D., Thompson, P. M., & Sowell, E. R. (2012). Along-tract statistics allow for enhanced tractography analysis. *NeuroImage, 59*(4), 3227–3242.
Conturo, T. E., Lori, N. F., Cull, T. S., Akbudak, E., Snyder, A. Z., Shimony, J. S., et al. (1999). Tracking neuronal fiber pathways in the living human brain. *Proceedings of the National Academy of Sciences of the United States of America, 96*(18), 10422–10427.
Dick, A. S., & Tremblay, P. (2012). Beyond the arcuate fasciculus: Consensus and controversy in the connectional anatomy of language. *Brain, 135*(Pt 12), 3529–3550.
Diehl, B., Busch, R. M., Duncan, J. S., Piao, Z., Tkach, J., & Luders, H. O. (2008). Abnormalities in diffusion tensor imaging of the uncinate fasciculus relate to reduced memory in temporal lobe epilepsy. *Epilepsia, 49*(8), 1409–1418.
Dohn, A., Garza-Villarreal, E. A., Chakravarty, M. M., Hansen, M., Lerch, J. P., & Vuust, P. (2015). Gray- and white-matter anatomy of absolute pitch possessors. *Cerebral Cortex, 25*(5), 1379–1388.
Francois, C., Ripolles, P., Bosch, L., Garcia-Alix, A., Muchart, J., Sierpowska, J., et al. (2016). Language learning and brain reorganization in a 3.5-year-old child with left perinatal stroke revealed using structural and functional connectivity. *Cortex, 77*, 95–118.
Frühholz, S., Gschwind, M., & Grandjean, D. (2015). Bilateral dorsal and ventral fiber pathways for the processing of affective prosody identified by probabilistic fiber tracking. *NeuroImage, 109*, 27–34.
Glasser, M. F., & Rilling, J. K. (2008). DTI tractography of the human brain's language pathways. *Cerebral Cortex, 18*(11), 2471–2482.
Halwani, G. F., Loui, P., Ruber, T., & Schlaug, G. (2011). Effects of practice and experience on the arcuate fasciculus: Comparing singers, instrumentalists, and non-musicians. *Frontiers in Psychology, 2*, 156.
Han, Y., Yang, H., Lv, Y. T., Zhu, C. Z., He, Y., Tang, H. H., et al. (2009). Gray matter density and white matter integrity in pianists' brain: A combined structural and diffusion tensor MRI study. *Neuroscience Letters, 459*(1), 3–6.
Harsan, L. A., Poulet, P., Guignard, B., Steibel, J., Parizel, N., de Sousa, P. L., et al. (2006). Brain dysmyelination and recovery assessment by noninvasive in vivo diffusion tensor magnetic resonance imaging. *Journal of Neuroscience Research, 83*(3), 392–402.
Henry, M., & McAuley, J. (2010). On the prevalence of congenital amusia. *Music Perception, 27*(5), 413–418.
Huang, H., Zhang, J., Jiang, H., Wakana, S., Poetscher, L., Miller, M. I., et al. (2005). DTI tractography based parcellation of white matter: Application to the mid-sagittal morphology of corpus callosum. *NeuroImage, 26*(1), 195–205.
Husain, F. T., Medina, R. E., Davis, C. W., Szymko-Bennett, Y., Simonyan, K., Pajor, N. M., et al. (2011). Neuroanatomical changes due to hearing loss and chronic tinnitus: A combined VBM and DTI study. *Brain Research, 1369*, 74–88.
Hyde, K. L., Lerch, J. P., Zatorre, R. J., Griffiths, T. D., Evans, A. C., & Peretz, I. (2007). Cortical thickness in congenital amusia: When less is better than more. *The Journal of Neuroscience, 27*(47), 13028–13032.
Hyde, K. L., Peretz, I., & Zatorre, R. J. (2008). Evidence for the role of the right auditory cortex in fine pitch resolution. *Neuropsychologia, 46*(2), 632–639.
Hyde, K. L., Zatorre, R. J., Griffiths, T. D., Lerch, J. P., & Peretz, I. (2006). Morphometry of the amusic brain: A two-site study. *Brain, 129*(10), 2562–2570.
Hyde, K. L., Zatorre, R. J., & Peretz, I. (2011). Functional MRI evidence of an abnormal neural network for pitch processing in congenital amusia. *Cerebral Cortex, 21*(2), 292–299.
Ivanova, M. V., Isaev, D. Y., Dragoy, O. V., Akinina, Y. S., Petrushevskiy, A. G., Fedina, O. N., et al. (2016). Diffusion-tensor imaging of major white matter tracts and their role in language processing in aphasia. *Cortex, 85*, 165–181.
Jafari, Z., Esmaili, M., Delbari, A., Mehrpour, M., & Mohajerani, M. H. (2017). Post-stroke acquired amusia: A comparison between right- and left-brain hemispheric damages. *Neurorehabilitation, 40*(2), 233–241.
Kalmus, H., & Fry, D. B. (1980). On tune deafness (dysmelodia): Frequency, development, genetics and musical background. *Annals of Human Genetics, 43*(4), 369–382.
Kier, E. L., Staib, L. H., Davis, L. M., & Bronen, R. A. (2004). MR imaging of the temporal stem: Anatomic dissection tractography of the uncinate fasciculus, inferior occipitofrontal fasciculus, and Meyer's loop of the optic radiation. *American Journal of Neuroradiology, 25*(5), 677–691.

Koelsch, S. (2014). Brain correlates of music-evoked emotions. *Nature Reviews. Neuroscience, 15*(3), 170–180.
Kummerer, D., Hartwigsen, G., Kellmeyer, P., Glauche, V., Mader, I., Kloppel, S., et al. (2013). Damage to ventral and dorsal language pathways in acute aphasia. *Brain, 136*(Pt 2), 619–629.
Leemans, A., & Jones, D. K. (2009). The B-matrix must be rotated when correcting for subject motion in DTI data. *Magnetic Resonance in Medicine, 61*(6), 1336–1349.
Leveque, Y., Fauvel, B., Groussard, M., Caclin, A., Albouy, P., Platel, H., et al. (2016). Altered intrinsic connectivity of the auditory cortex in congenital amusia. *Journal of Neurophysiology, 116*(1), 88–97.
Liegeois-Chauvel, C., Peretz, I., Babai, M., Laguitton, V., & Chauvel, P. (1998). Contribution of different cortical areas in the temporal lobes to music processing. *Brain, 121*(Pt 10), 1853–1867.
Lima, C. F., Brancatisano, O., Fancourt, A., Müllensiefen, D., Scott, S. K., Warren, J. D., et al. (2016). Impaired socio-emotional processing in a developmental music disorder. *Scientific Reports, 6*, 34911.
Lopez-Barroso, D., Catani, M., Ripolles, P., Dell'Acqua, F., Rodriguez-Fornells, A., & de Diego-Balaguer, R. (2013). Word learning is mediated by the left arcuate fasciculus. *Proceedings of the National Academy of Sciences of the United States of America, 110*(32), 13168–13173.
Loui, P. A. (2015). Dual-stream neuroanatomy of singing. *Music Perception, 32*(3), 232–241.
Loui, P., Alsop, D., & Schlaug, G. (2009). Tone deafness: A new disconnection syndrome? *The Journal of Neuroscience, 29*(33), 10215–10220.
Loui, P., Guenther, F. H., Mathys, C., & Schlaug, G. (2008). Action-perception mismatch in tone-deafness. *Current Biology, 18*(8), R331–R332.
Loui, P., Li, H. C., Hohmann, A., & Schlaug, G. (2011). Enhanced cortical connectivity in absolute pitch musicians: A model for local hyperconnectivity. *Journal of Cognitive Neuroscience, 23*(4), 1015–1026.
Marin, M. M., Gingras, B., & Stewart, L. (2012). Perception of musical timbre in congenital amusia: Categorization, discrimination and short-term memory. *Neuropsychologia, 50*(3), 367–378.
Martino, J., Brogna, C., Robles, S. G., Vergani, F., & Duffau, H. (2010). Anatomic dissection of the inferior fronto-occipital fasciculus revisited in the lights of brain stimulation data. *Cortex, 46*(5), 691–699.
Mitchell, R. L., & Ross, E. D. (2008). fMRI evidence for the effect of verbal complexity on lateralisation of the neural response associated with decoding prosodic emotion. *Neuropsychologia, 46*(12), 2880–2887.
Musso, M., Weiller, C., Horn, A., Glauche, V., Umarova, R., Hennig, J., et al. (2015). A single dual-stream framework for syntactic computations in music and language. *NeuroImage, 117*, 267–283.
Nichols, T. E., & Holmes, A. P. (2002). Nonparametric permutation tests for functional neuroimaging: A primer with examples. *Human Brain Mapping, 15*(1), 1–25.
Nys, G. M., van Zandvoort, M. J., de Kort, P. L., Jansen, B. P., de Haan, E. H., & Kappelle, L. J. (2007). Cognitive disorders in acute stroke: Prevalence and clinical determinants. *Cerebrovascular Diseases, 23*(5–6), 408–416.
Oechslin, M. S., Imfeld, A., Loenneker, T., Meyer, M., & Jancke, L. (2010). The plasticity of the superior longitudinal fasciculus as a function of musical expertise: A diffusion tensor imaging study. *Frontiers in Human Neuroscience, 3*, 76.
Omigie, D., Müllensiefen, D., & Stewart, L. (2012). The experience of music in congenital amusia. *Music Perception, 30*(1), 1–18.
Patterson, R. D., Uppenkamp, S., Johnsrude, I. S., & Griffiths, T. D. (2002). The processing of temporal pitch and melody information in auditory cortex. *Neuron, 36*(4), 767–776.
Perani, D., Saccuman, M. C., Scifo, P., Anwander, A., Spada, D., Baldoli, C., et al. (2011). Neural language networks at birth. *Proceedings of the National Academy of Sciences of the United States of America, 108*(38), 16056–16061.
Peretz, I., Champod, A. S., & Hyde, K. (2003). Varieties of musical disorders. The montreal battery of evaluation of amusia. *Annals of the New York Academy of Sciences, 999*, 58–75.
Rauschecker, J. P. (2014). Is there a tape recorder in your head? How the brain stores and retrieves musical melodies. *Frontiers in Systems Neuroscience, 8*, 149.
Rauschecker, J. P., & Scott, S. K. (2009). Maps and streams in the auditory cortex: Nonhuman primates illuminate human speech processing. *Nature Neuroscience, 12*(6), 718–724.
Rizio, A. A., & Diaz, M. T. (2016). Language, aging, and cognition: Frontal aslant tract and superior longitudinal fasciculus contribute toward working memory performance in older adults. *NeuroReport, 27*(9), 689–693.
Rorden, C., & Karnath, H. O. (2004). Using human brain lesions to infer function: A relic from a past era in the fMRI age? *Nature Reviews. Neuroscience, 5*(10), 813–819.
Ross, E. D. (2010). Cerebral localization of functions and the neurology of language: Fact versus fiction or is it something else? *The Neuroscientist, 16*(3), 222–243.
Ross, E. D., & Monnot, M. (2008). Neurology of affective prosody and its functional-anatomic organization in right hemisphere. *Brain and Language, 104*(1), 51–74.
Rosslau, K., Steinwede, D., Schröder, C., Herholz, S. C., Lappe, C., Dobel, C., et al. (2015). Clinical investigations of receptive and expressive musical functions after stroke. *Frontiers in Psychology, 6*, 768.
Royal, I., Vuvan, D. T., Zendel, B. R., Robitaille, N., Schonwiesner, M., & Peretz, I. (2016). Activation in the right inferior parietal lobule reflects the representation of musical structure beyond simple pitch discrimination. *PLoS One, 11*(5), e0155291.
Ruber, T., Lindenberg, R., & Schlaug, G. (2015). Differential adaptation of descending motor tracts in musicians. *Cerebral Cortex, 25*(6), 1490–1498.
Rueckert, D., Sonoda, L. I., Hayes, C., Hill, D. L., Leach, M. O., & Hawkes, D. J. (1999). Nonrigid registration using free-form deformations: Application to breast MR images. *IEEE Transactions on Medical Imaging, 18*(8), 712–721.
Sammler, D., Grosbras, M. H., Anwander, A., Bestelmeyer, P. E., & Belin, P. (2015). Dorsal and ventral pathways for prosody. *Current Biology, 25*(23), 3079–3085.
Samson, F., Zeffiro, T. A., Toussaint, A., & Belin, P. (2011). Stimulus complexity and categorical effects in human auditory cortex: An activation likelihood estimation meta-analysis. *Frontiers in Psychology, 1*, 241.
Särkämö, T., Tervaniemi, M., Laitinen, S., Forsblom, A., Soinila, S., Mikkonen, M., et al. (2008). Music listening enhances cognitive recovery and mood after middle cerebral artery stroke. *Brain, 131*, 866–876.
Särkämö, T., Tervaniemi, M., Soinila, S., Autti, T., Silvennoinen, H. M., Laine, M., et al. (2009). Cognitive deficits associated with acquired amusia after stroke: A neuropsychological follow-up study. *Neuropsychologia, 47*(12), 2642–2651.
Sarubbo, S., De Benedictis, A., Maldonado, I. L., Basso, G., & Duffau, H. (2013). Frontal terminations for the inferior fronto-occipital fascicle: Anatomical dissection, DTI study and functional considerations on a multi-component bundle. *Brain Structure & Function, 218*(1), 21–37.
Saur, D., Kreher, B. W., Schnell, S., Kummerer, D., Kellmeyer, P., Vry, M. S., et al. (2008). Ventral and dorsal pathways for

language. *Proceedings of the National Academy of Sciences of the United States of America, 105*(46), 18035–18040.
Schlaug, G., Jancke, L., Huang, Y., Staiger, J. F., & Steinmetz, H. (1995). Increased corpus callosum size in musicians. *Neuropsychologia, 33*(8), 1047–1055.
Schmahmann, J. D., & Pandya, D. N. (2006). *Fiber pathways of the brain*. Oxford University Press.
Schmithorst, V. J. (2005). Separate cortical networks involved in music perception: Preliminary functional MRI evidence for modularity of music processing. *NeuroImage, 25*(2), 444–451.
Schmithorst, V. J., & Wilke, M. (2002). Differences in white matter architecture between musicians and non-musicians: A diffusion tensor imaging study. *Neuroscience Letters, 321*(1–2), 57–60.
Schuppert, M., Münte, T. F., Wieringa, B. M., & Altenmüller, E. (2000). Receptive amusia: Evidence for cross-hemispheric neural networks underlying music processing strategies. *Brain, 123*(Pt 3), 546–559.
Sierpowska, J., Gabarros, A., Fernandez-Coello, A., Camins, A., Castaner, S., Juncadella, M., et al. (2015). Morphological derivation overflow as a result of disruption of the left frontal aslant white matter tract. *Brain and Language, 142*, 54–64.
Sierpowska, J., Gabarros, A., Fernandez-Coello, A., Camins, A., Castaner, S., Juncadella, M., et al. (2017). Words are not enough: Nonword repetition as an indicator of arcuate fasciculus integrity during brain tumor resection. *Journal of Neurosurgery, 126*(2), 435–445.
Sihvonen, A. J., Ripollés, P., Leo, V., Rodríguez-Fornells, A., Soinila, S., & Särkämö, T. (2016). Neural basis of acquired amusia and its recovery after stroke. *Journal of Neuroscience, 36*(34), 8872–8881.
Smith, S. M. (2002). Fast robust automated brain extraction. *Human Brain Mapping, 17*(3), 143–155.
Smith, S. M., Jenkinson, M., Johansen-Berg, H., Rueckert, D., Nichols, T. E., Mackay, C. E., et al. (2006). Tract-based spatial statistics: Voxelwise analysis of multi-subject diffusion data. *NeuroImage, 31*(4), 1487–1505.
Smith, S. M., Jenkinson, M., Woolrich, M. W., Beckmann, C. F., Behrens, T. E., Johansen-Berg, H., et al. (2004). Advances in functional and structural MR image analysis and implementation as FSL. *NeuroImage, 23*(Suppl. 1), S208–S219.
Smith, S. M., & Nichols, T. E. (2009). Threshold-free cluster enhancement: Addressing problems of smoothing, threshold dependence and localisation in cluster inference. *NeuroImage, 44*(1), 83–98.
Song, S. K., Sun, S. W., Ramsbottom, M. J., Chang, C., Russell, J., & Cross, A. H. (2002). Dysmyelination revealed through MRI as increased radial (but unchanged axial) diffusion of water. *NeuroImage, 17*(3), 1429–1436.
Song, S. K., Yoshino, J., Le, T. Q., Lin, S. J., Sun, S. W., Cross, A. H., et al. (2005). Demyelination increases radial diffusivity in corpus callosum of mouse brain. *NeuroImage, 26*(1), 132–140.
Stewart, L. (2008). Fractionating the musical mind: Insights from congenital amusia. *Current Opinion in Neurobiology, 18*(2), 127–130.
Stewart, L., von Kriegstein, K., Warren, J. D., & Griffiths, T. D. (2006). Music and the brain: Disorders of musical listening. *Brain, 129*(Pt 10), 2533–2553.
Thiebaut de Schotten, M., Dell'Acqua, F., Valabregue, R., & Catani, M. (2012). Monkey to human comparative anatomy of the frontal lobe association tracts. *Cortex, 48*(1), 82–96.
Thiebaut de Schotten, M., Kinkingnehun, S., Delmaire, C., Lehericy, S., Duffau, H., Thivard, L., et al. (2008). Visualization of disconnection syndromes in humans. *Cortex, 44*(8), 1097–1103.
Thompson, W. F., Marin, M. M., & Stewart, L. (2012). Reduced sensitivity to emotional prosody in congenital amusia rekindles the musical protolanguage hypothesis. *Proceedings of the National Academy of Sciences of the United States of America, 109*(46), 19027–19032.
Turken, A. U., & Dronkers, N. F. (2011). The neural architecture of the language comprehension network: Converging evidence from lesion and connectivity analyses. *Frontiers in Systems Neuroscience, 5*, 1.
Vaquero, L., Rodriguez-Fornells, A., & Reiterer, S. M. (2016). The left, the better: White-matter brain integrity predicts foreign language imitation ability. *Cerebral Cortex*.
Vassal, F., Schneider, F., Boutet, C., Jean, B., Sontheimer, A., & Lemaire, J. J. (2016). Combined DTI tractography and functional MRI study of the language connectome in healthy volunteers: Extensive mapping of white matter fascicles and cortical activations. *PLoS One, 11*(3), e0152614.
Von Der Heide, R. J., Skipper, L. M., Klobusicky, E., & Olson, I. R. (2013). Dissecting the uncinate fasciculus: Disorders, controversies and a hypothesis. *Brain, 136*(Pt 6), 1692–1707.
Westerhausen, R., Gruner, R., Specht, K., & Hugdahl, K. (2009). Functional relevance of interindividual differences in temporal lobe callosal pathways: A DTI tractography study. *Cerebral Cortex, 19*(6), 1322–1329.
Wildgruber, D., Ackermann, H., Kreifelts, B., & Ethofer, T. (2006). Cerebral processing of linguistic and emotional prosody: fMRI studies. *Progress in Brain Research, 156*, 249–268.
Yu, C., Zhu, C., Zhang, Y., Chen, H., Qin, W., Wang, M., et al. (2009). A longitudinal diffusion tensor imaging study on Wallerian degeneration of corticospinal tract after motor pathway stroke. *NeuroImage, 47*(2), 451–458.
Zamm, A., Schlaug, G., Eagleman, D. M., & Loui, P. (2013). Pathways to seeing music: Enhanced structural connectivity in colored-music synesthesia. *NeuroImage, 74*, 359–366.
Zatorre, R. J., Belin, P., & Penhune, V. B. (2002). Structure and function of auditory cortex: Music and speech. *Trends in Cognitive Sciences, 6*(1), 37–46.
Zatorre, R. J., Chen, J. L., & Penhune, V. B. (2007). When the brain plays music: Auditory-motor interactions in music perception and production. *Nature Reviews Neuroscience, 8*(7), 547–558.
Zatorre, R. J., & Salimpoor, V. N. (2013). From perception to pleasure: Music and its neural substrates. *Proceedings of the National Academy of Sciences of the United States of America, 110*(Suppl. 2), 10430–10437.
Zhao, Y., Chen, X., Zhong, S., Cui, Z., Gong, G., Dong, Q., et al. (2016). Abnormal topological organization of the white matter network in Mandarin speakers with congenital amusia. *Scientific Reports, 6*, 26505.

Please cite this article in press as: Sihvonen, A. J., et al., Tracting the neural basis of music: Deficient structural connectivity underlying acquired amusia, Cortex (2017), https://doi.org/10.1016/j.cortex.2017.09.028